

Kardiologie heute

Symposium im Unfallkrankenhaus Berlin
am 07. Dezember 2012



Bildgebung in der invasiven Elektrophysiologie

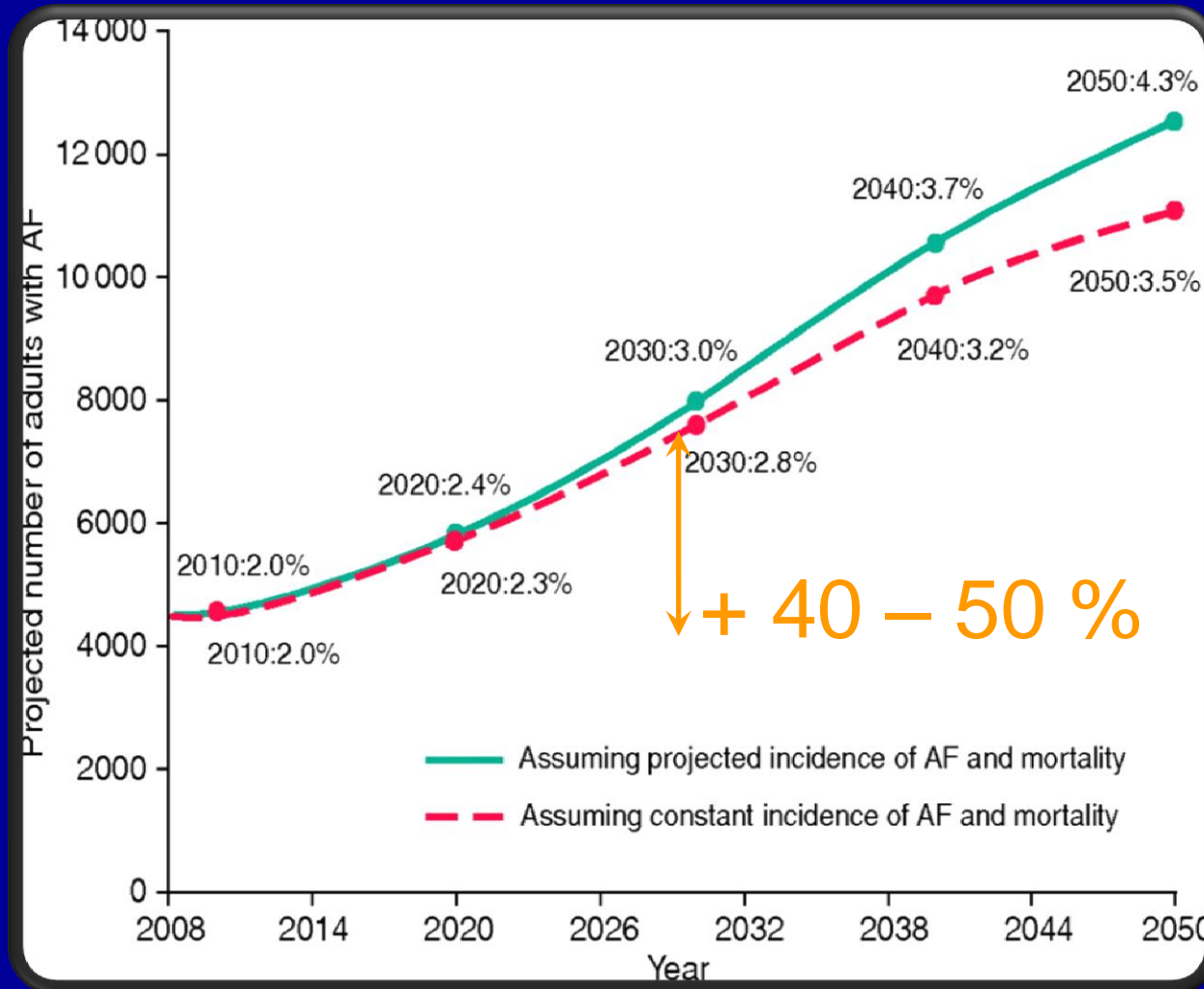


Philipp Sommer, Herzzentrum
Universität Leipzig
Abtlg. für Elektrophysiologie

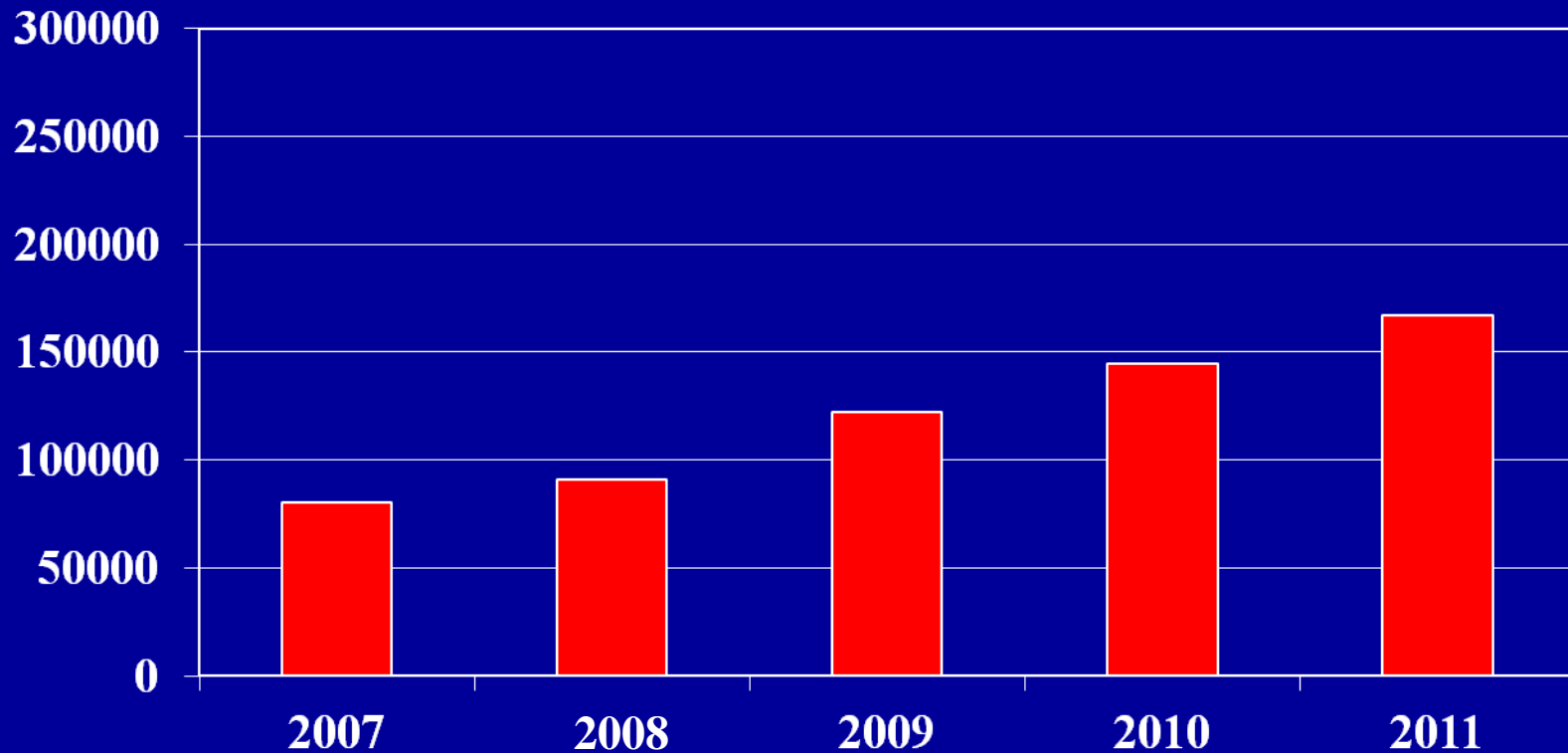
Agenda:

- 1.) Einleitung
- 2.) Rolle der CT
- 3.) Rolle der MRT in Planung und Durchführung von Ablationen
- 4.) Reduktion der Fluoroskopiezeiten

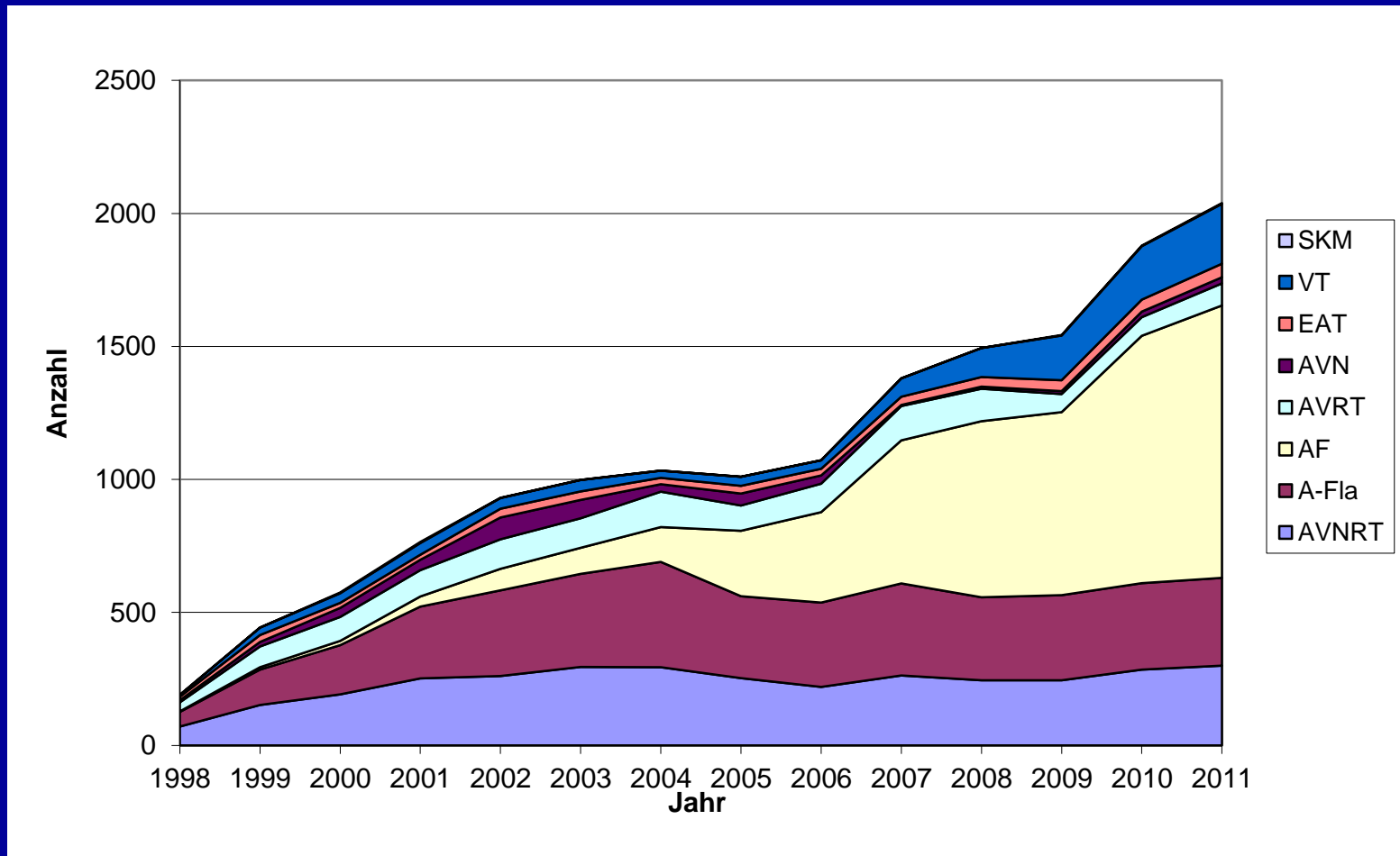
Epidemiologie von Vorhofflimmern



Katheterablationen in Europa 2007 - 2011



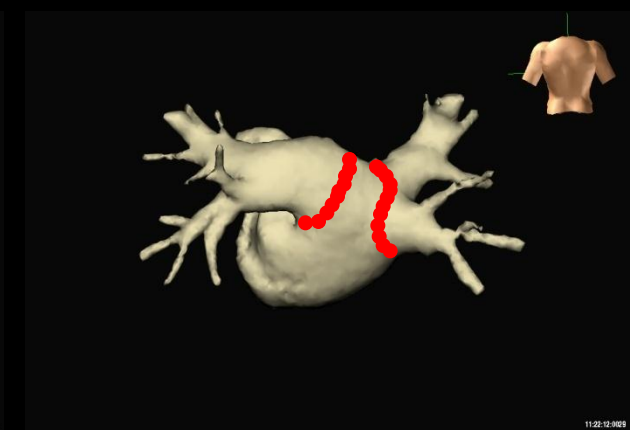
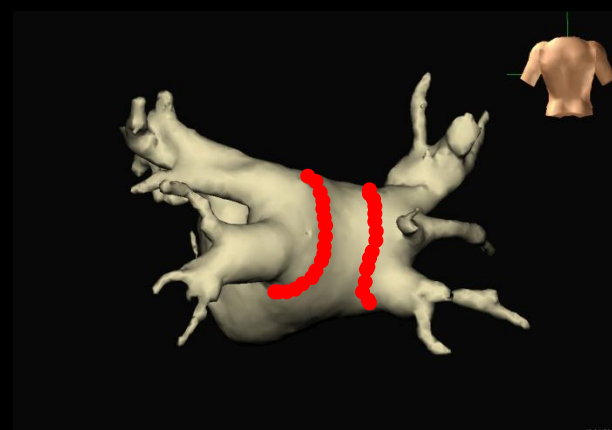
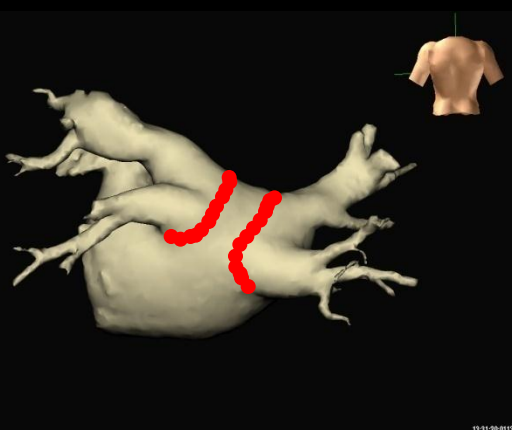
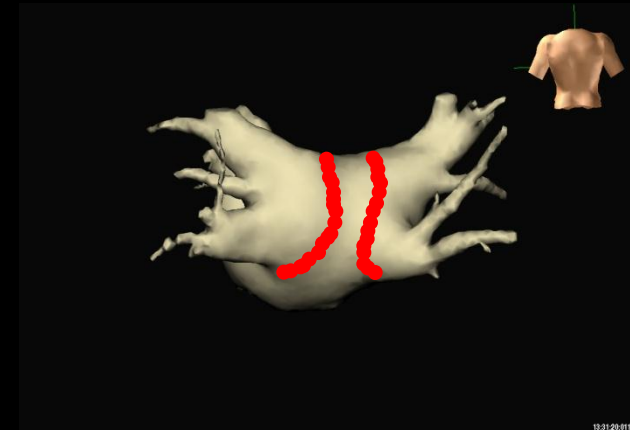
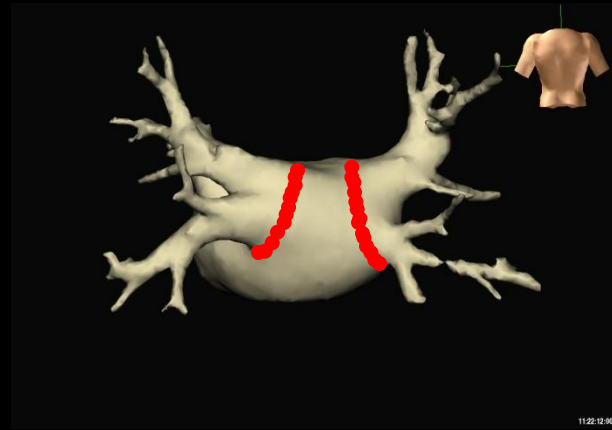
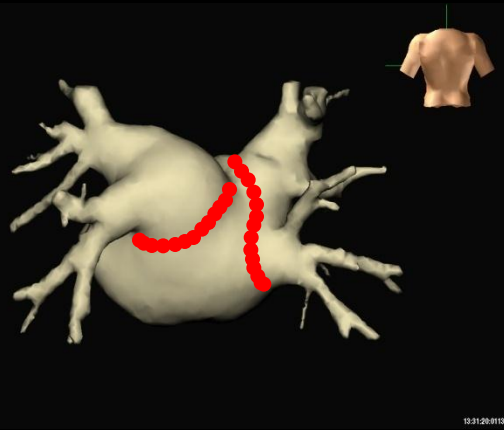
Katheterablationen im HZL Leipzig 1998 - 2011



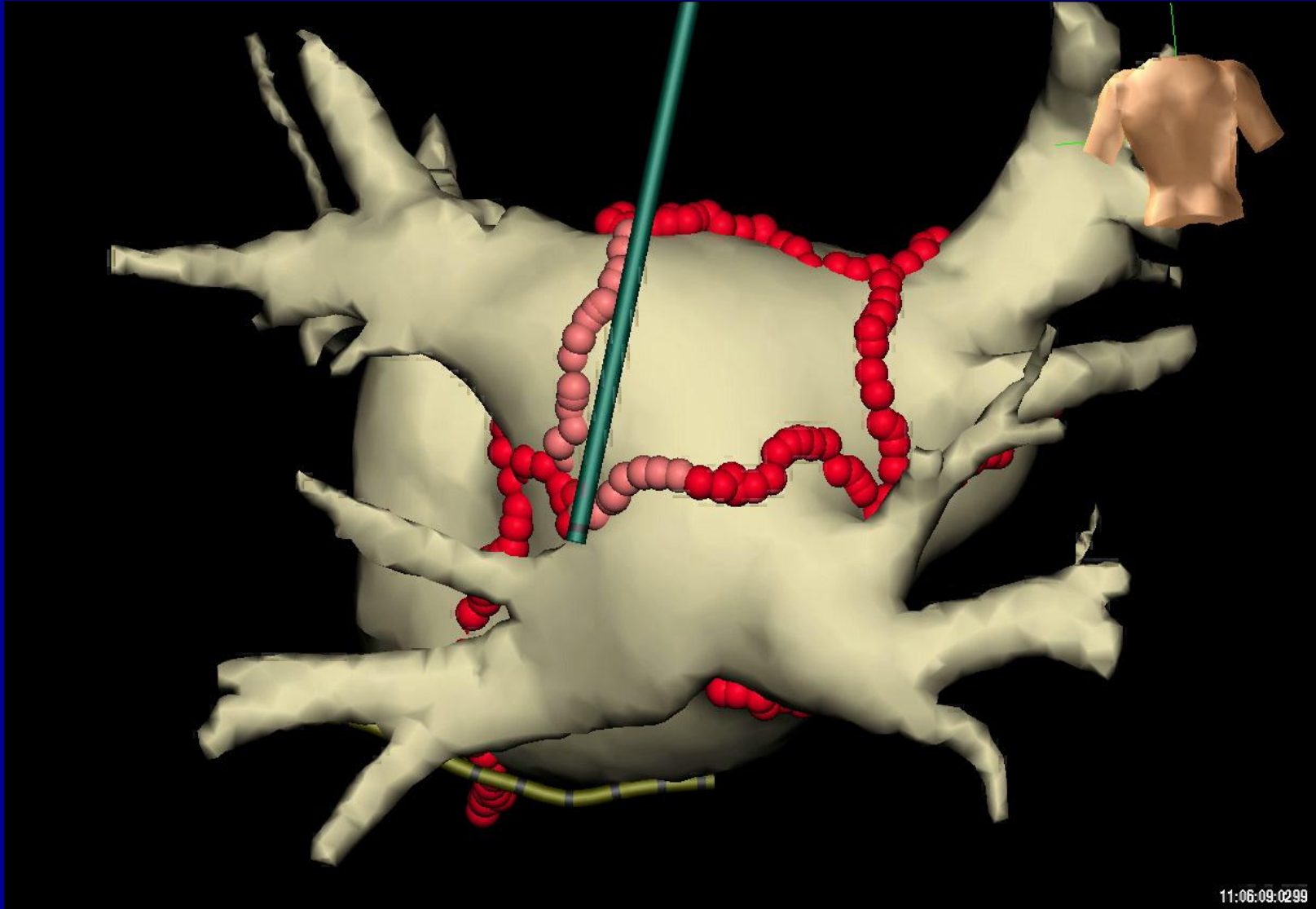
Agenda:

- 1.) Einleitung
- 2.) Rolle der CT
- 3.) Rolle der MRT in Planung und Durchführung von Ablationen
- 4.) Reduktion der Fluoroskopiezeiten

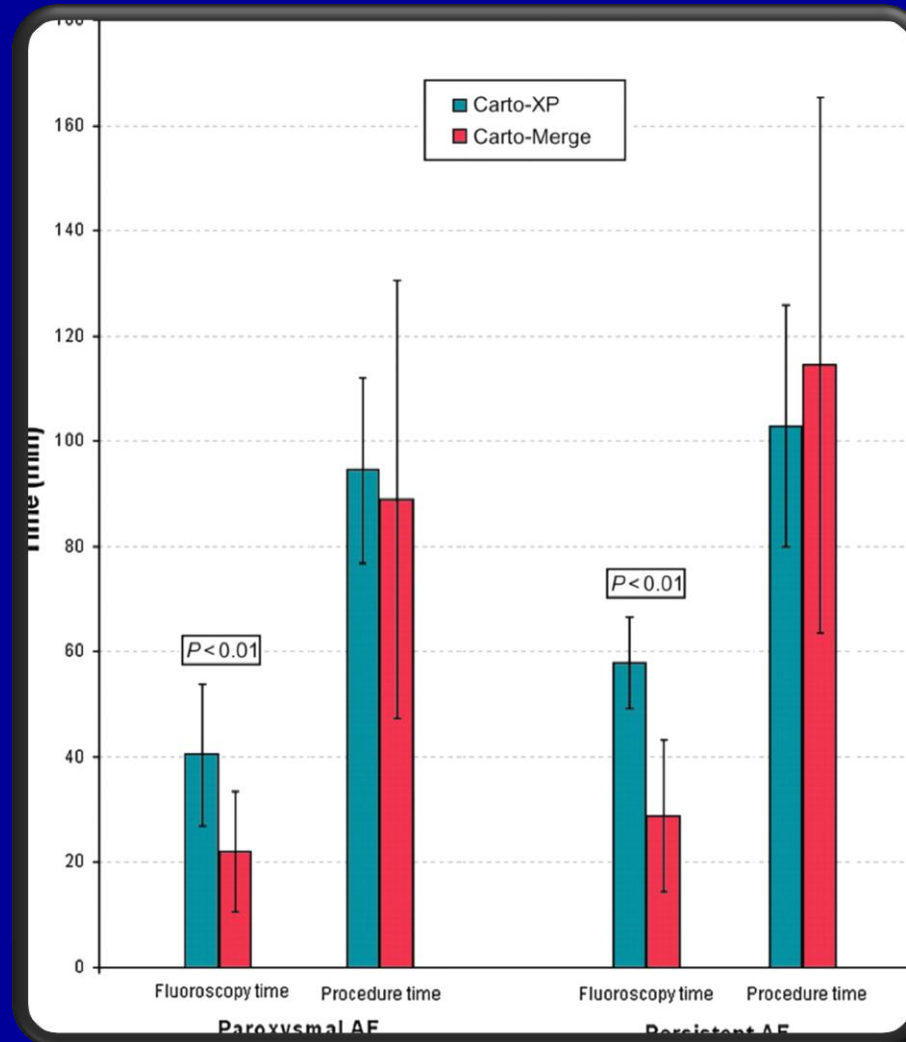
Individuelle Anatomie der PV und des LA



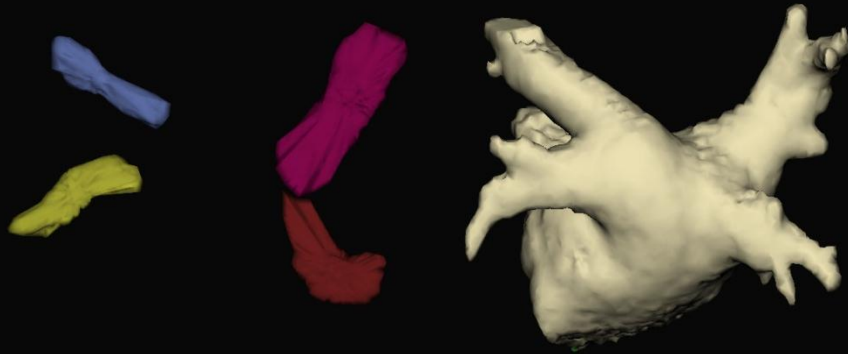
Electroanatomical mapping vs. CT integration



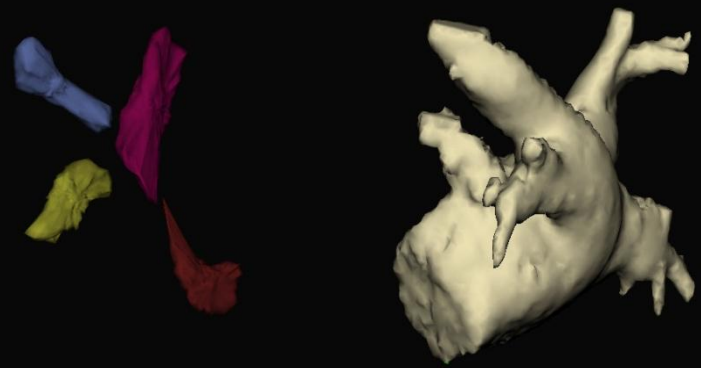
Fluoroskopie- und Prozedurzeiten bei PAF (li.) und CAF (re.)



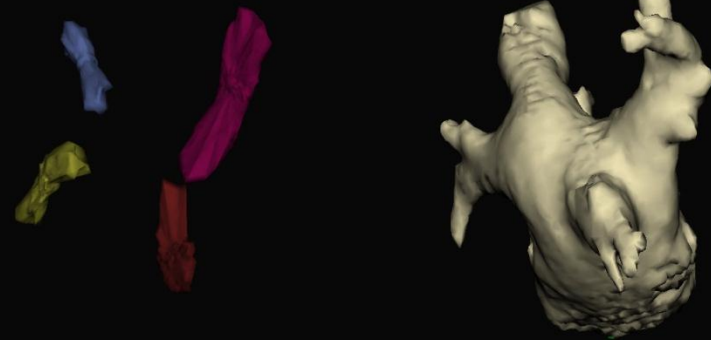
Registrierung der PV Geometrien mit CT Modell



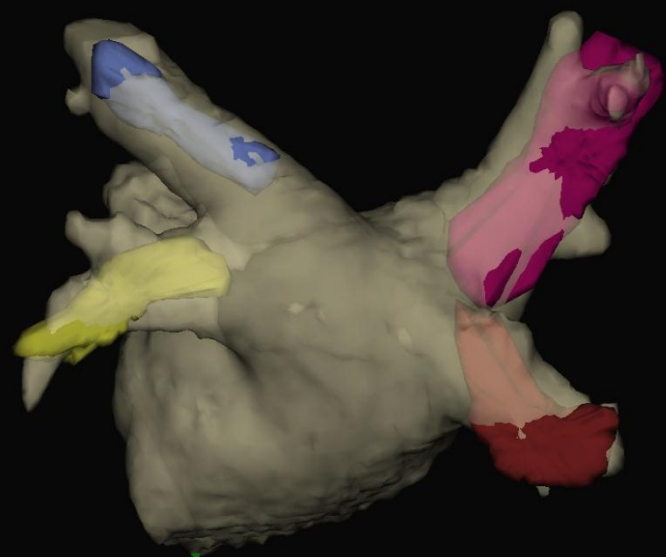
PA



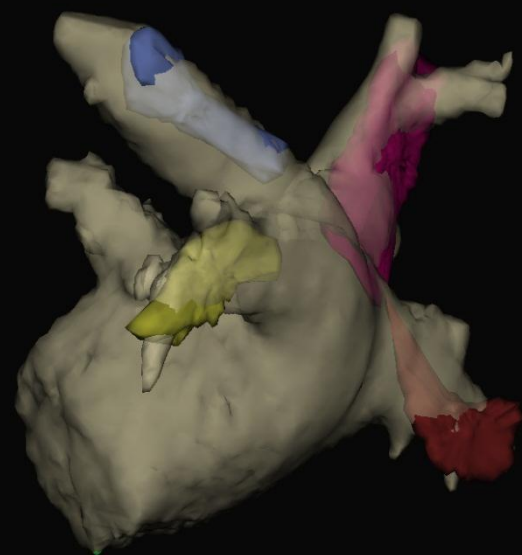
LPO



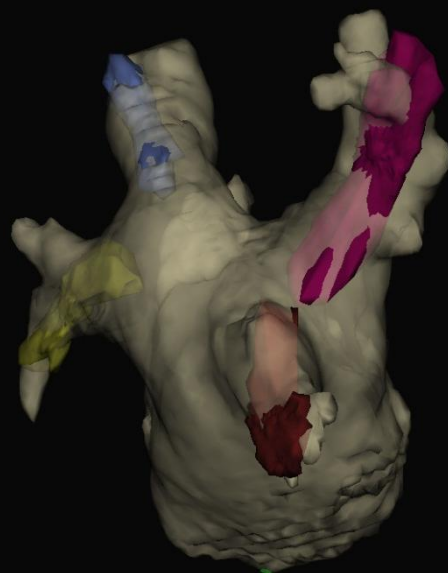
RPO



PA



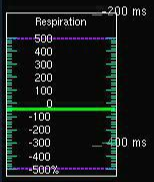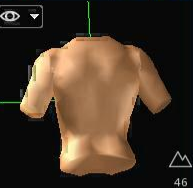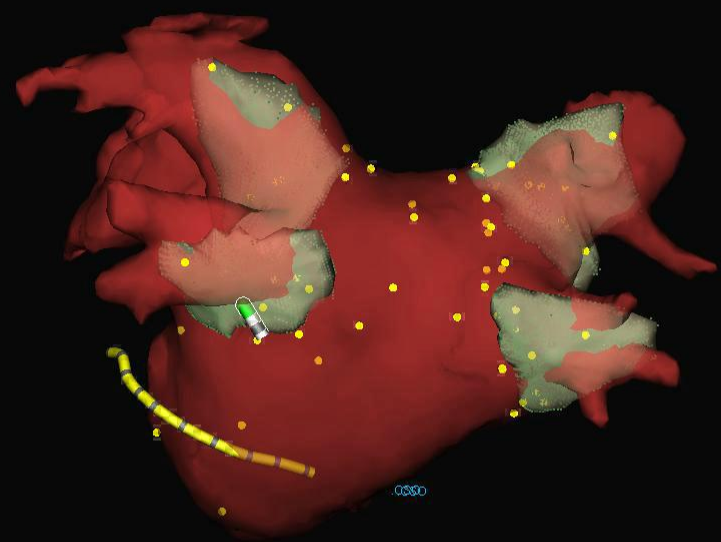
LPO



RPO

paroxysmal AF 2009 May 06
check fusion

PPI
LAT Isochronal Map



Electrode spacing: | Distal | D - 2 | 2 - 3 | 3 - 4 |
Nominal (mm) 4.0 1.5

Fiducials	Used
FID1	<input checked="" type="checkbox"/>
FID2	<input checked="" type="checkbox"/>
FID3	<input checked="" type="checkbox"/>
FID4	<input checked="" type="checkbox"/>
FID5	<input checked="" type="checkbox"/>
FID6	<input checked="" type="checkbox"/>
FID7	<input checked="" type="checkbox"/>
FID8	<input checked="" type="checkbox"/>
FID9	<input checked="" type="checkbox"/>
FID12	<input checked="" type="checkbox"/>
FID13	<input checked="" type="checkbox"/>

- Registration Actions
- Add At Surface
 - Add At EnGuide
 - Move
 - Select

Compute

Apply

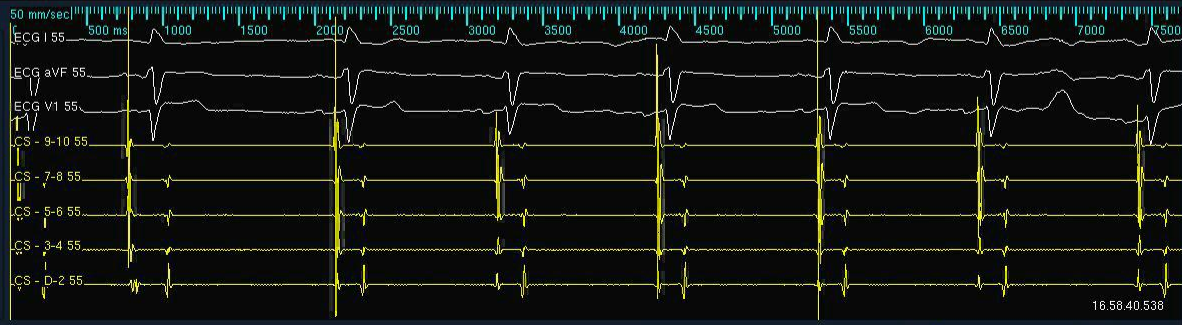Delete Fiducials

- Use Fiducial
- Show Fiducials
- Show Points

Traces

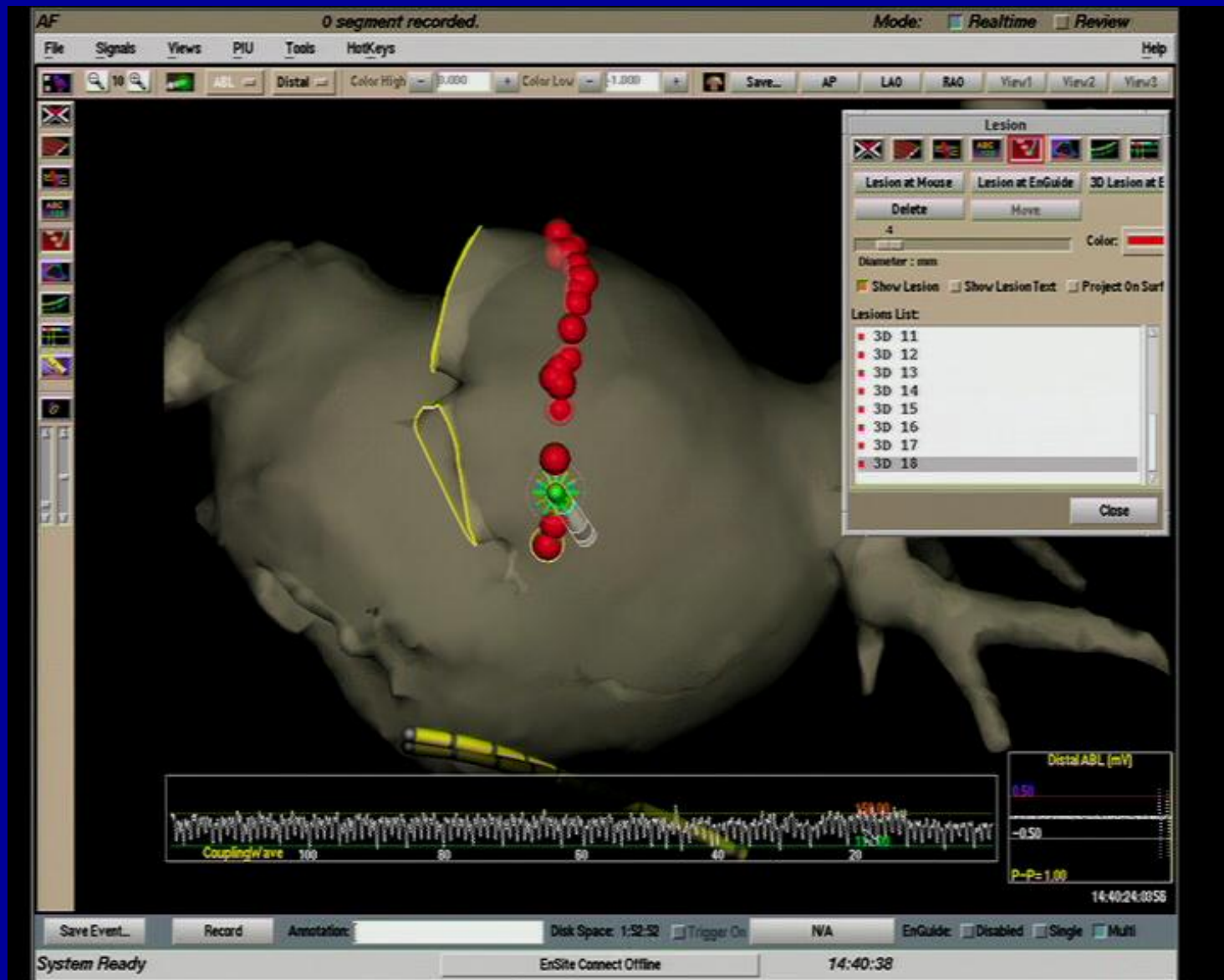
- Signal
- ECG <24>
- Respiration <1>
- CS <10>
- RV <2>
- Spir <10>
- ABL <4>
- Oes <2>

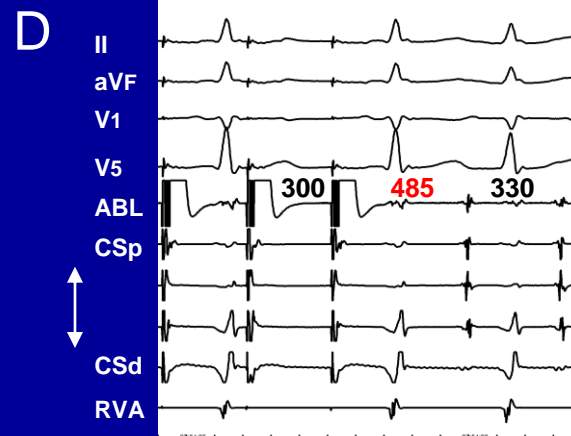
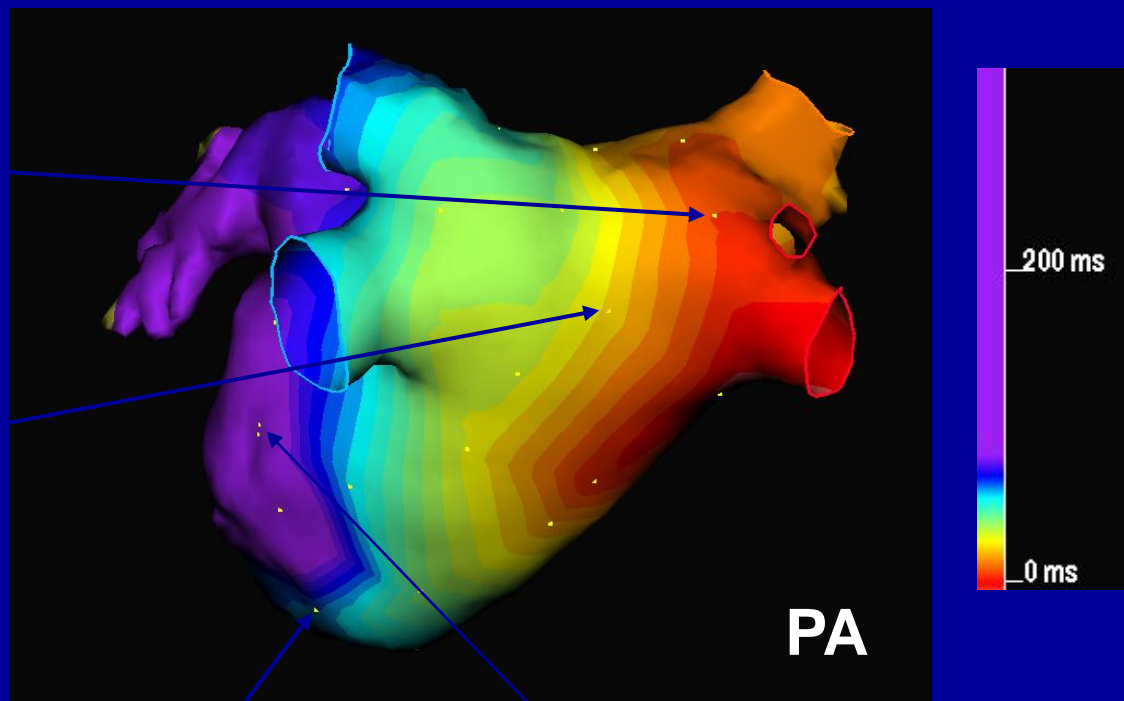
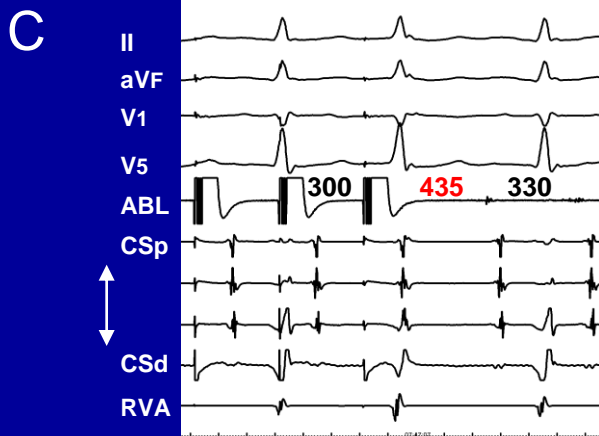
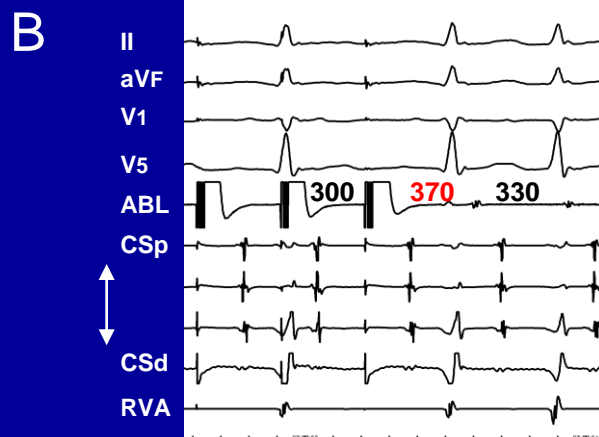
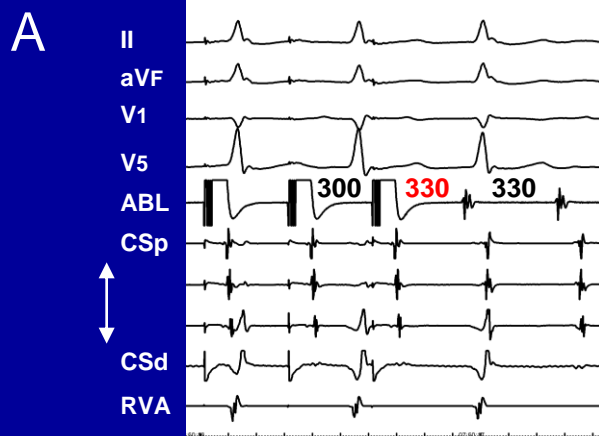
Properties
ECG <24>



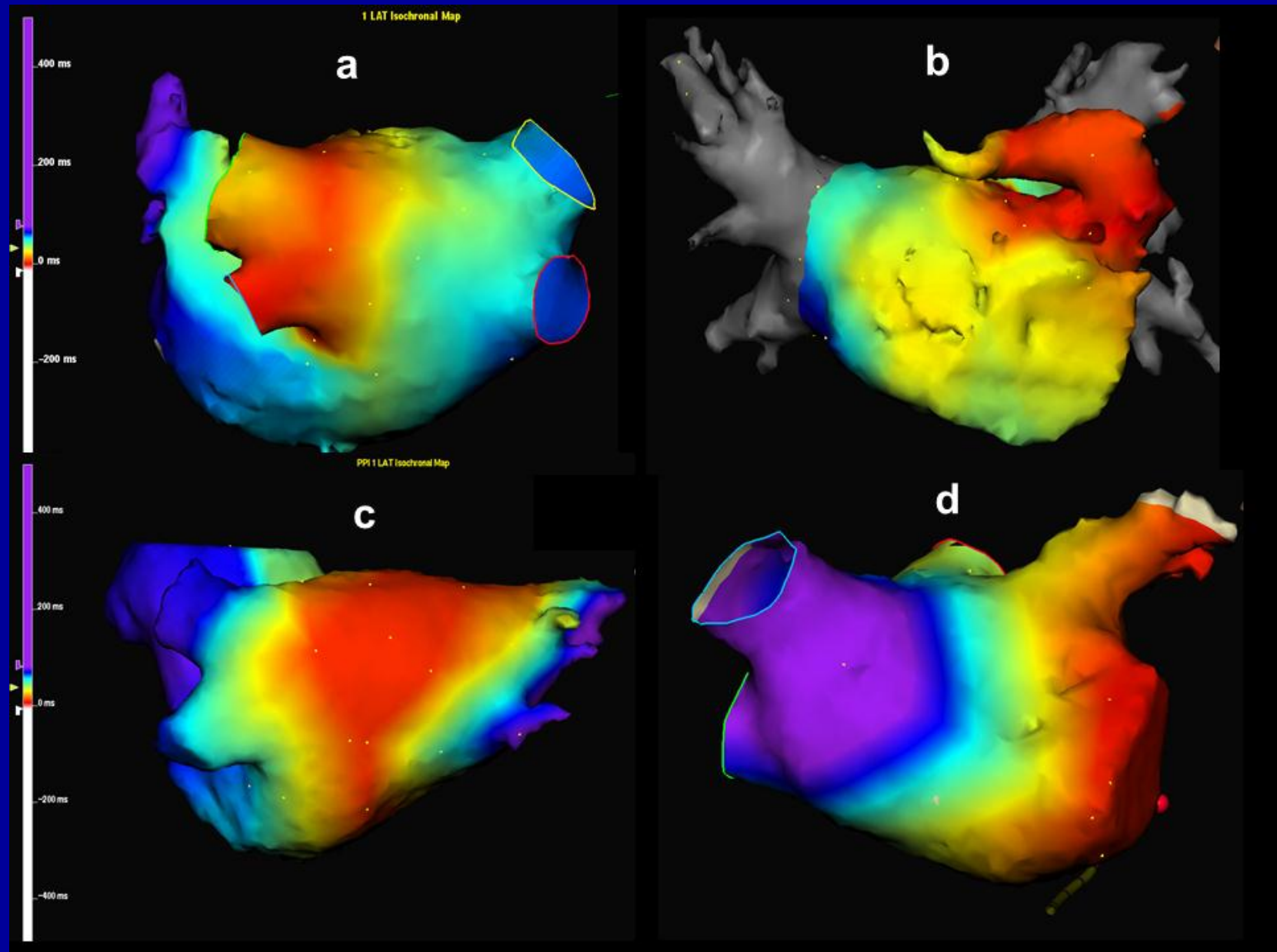
Segment check fusion 1:1

Ablation im registrierten CT/ MRT Modell

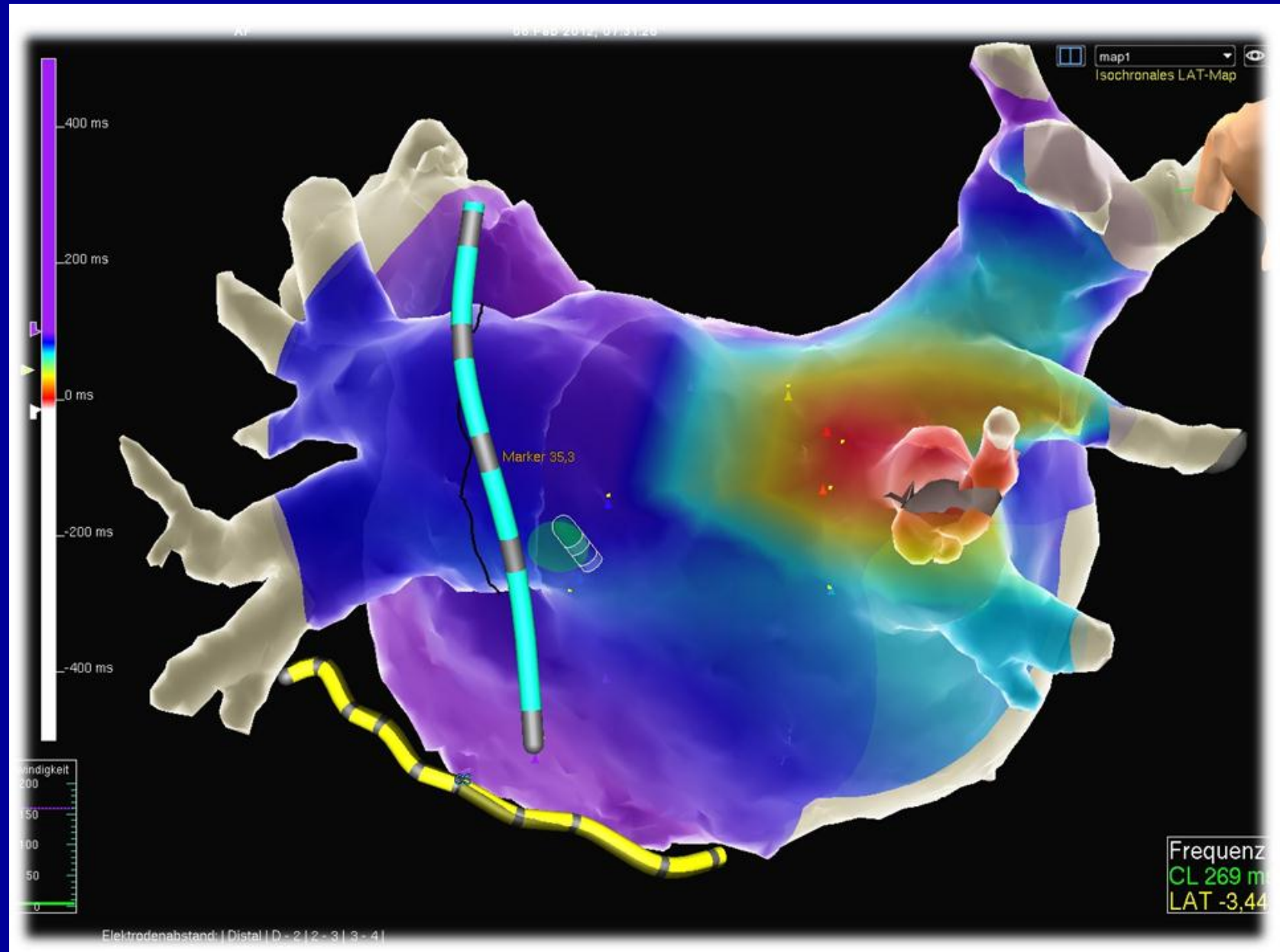




Stellenwert bildgebender Verfahren in der invasiven EP



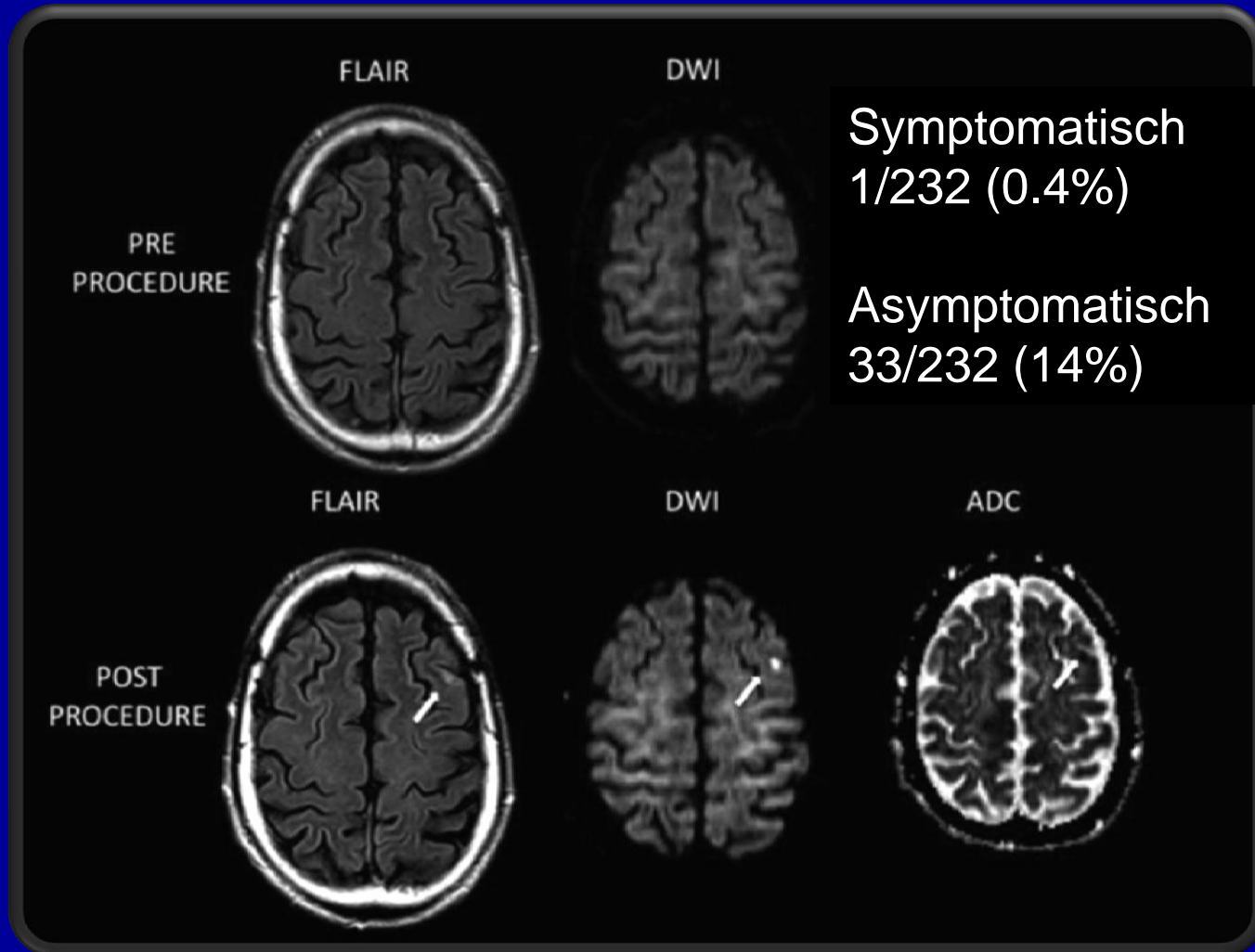
Stellenwert bildgebender Verfahren in der invasiven EP



Agenda:

- 1.) Einleitung
- 2.) Rolle der CT
- 3.) Rolle der MRT in Planung und Durchführung von Ablationen
- 4.) Reduktion der Fluoroskopiezeiten

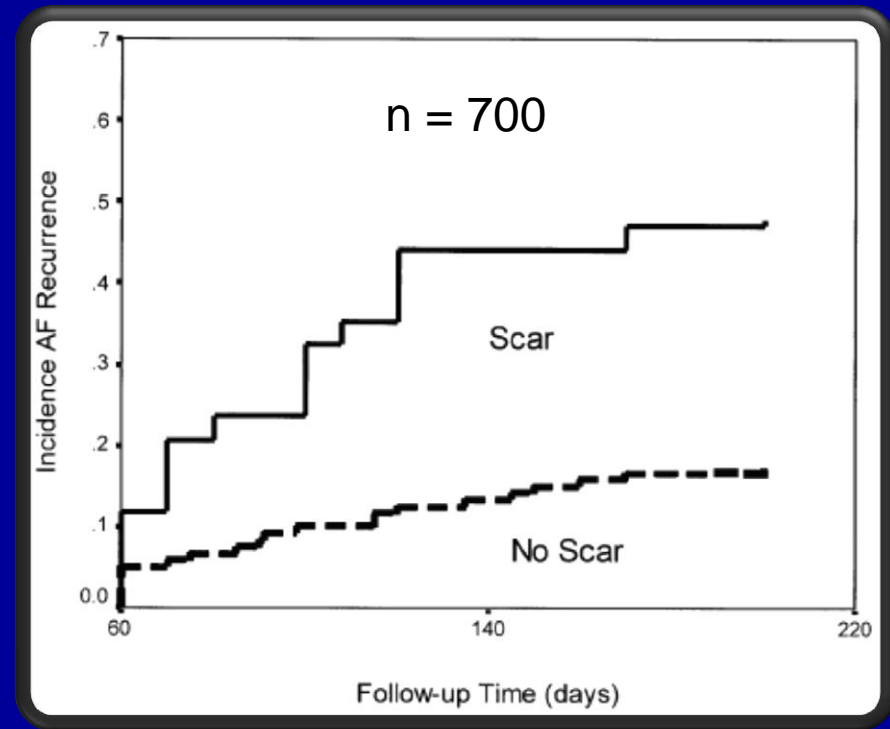
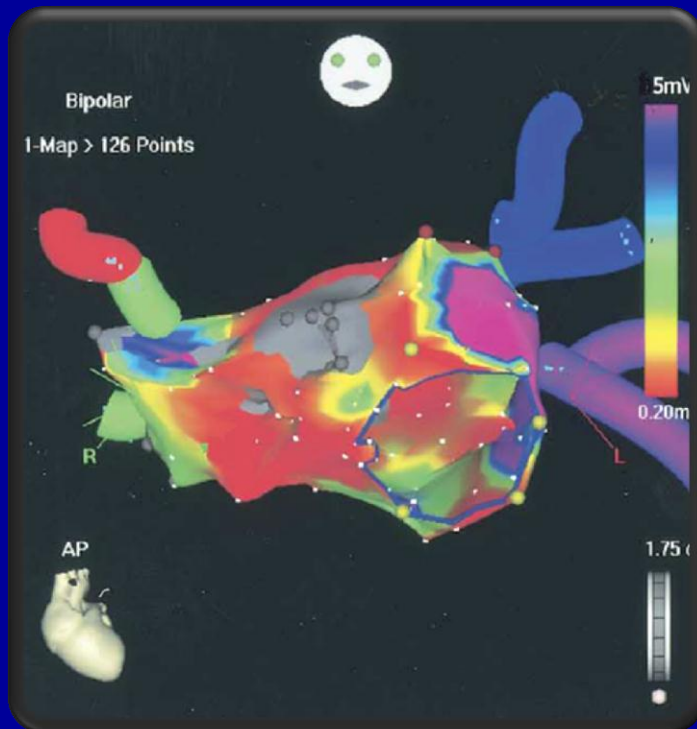
Detektion asymptomatischer Thrombembolien



MRT zur Narbenidentifikation

- Begrenzte Aussagekraft der klinischen Klassifikation des Vorhofflimmerns in paroxysmal/ persistierend.
- Bedeutung linearer Läsionen/ CFAE Ablationen unklar
- PV-abhängiges vs. substratabhängiges Vorhofflimmern
- Limitierter prädiktiver Wert anderer Parameter wie LA Größe, Anamnesedauer, Alter des Patienten)

Visualisierung und Bedeutung von Narben im LA



Voltage definitions:

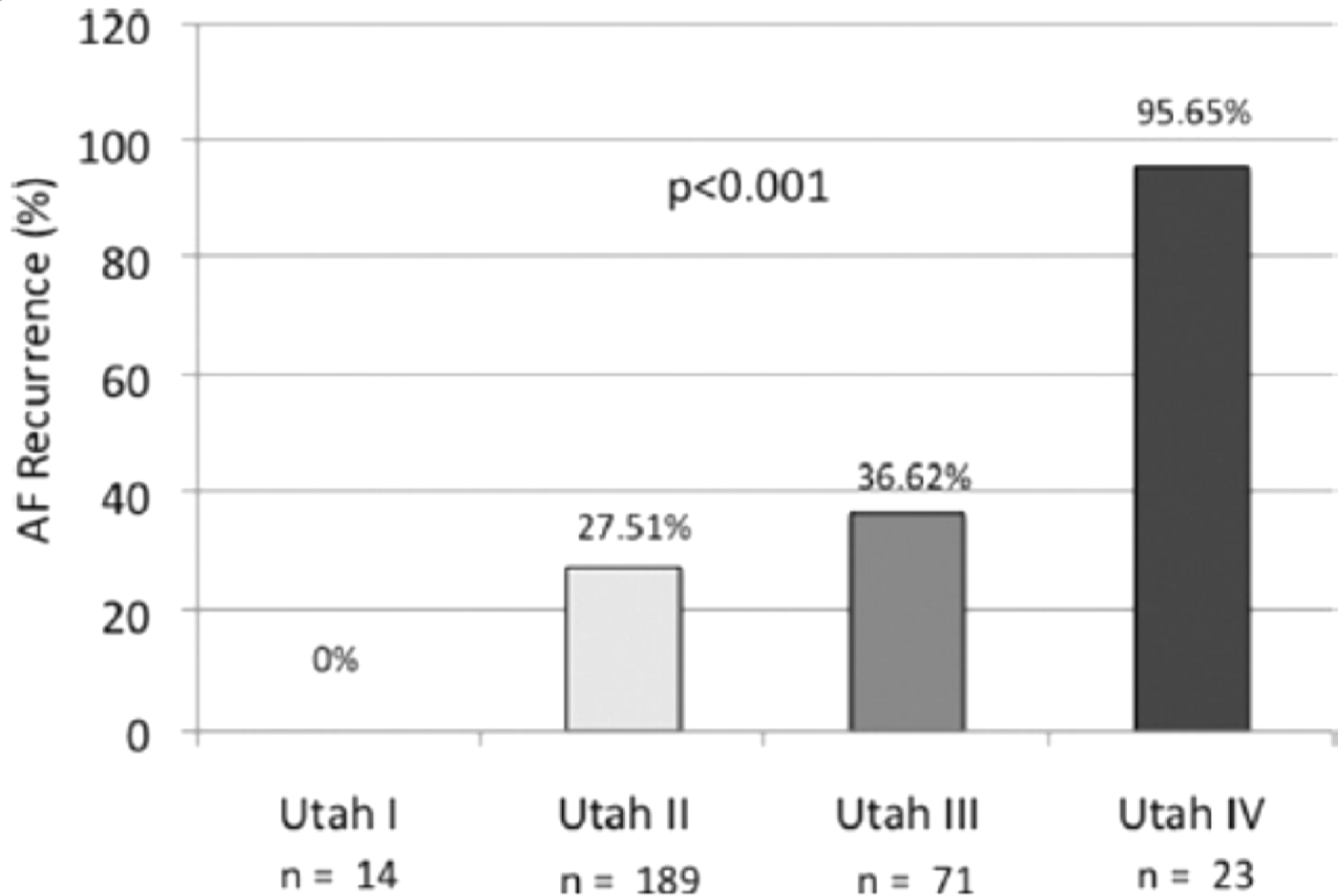
scar < 0.05 mV

diseased myocardium < 0.5 mV

healthy myocardium > 0.5 mV

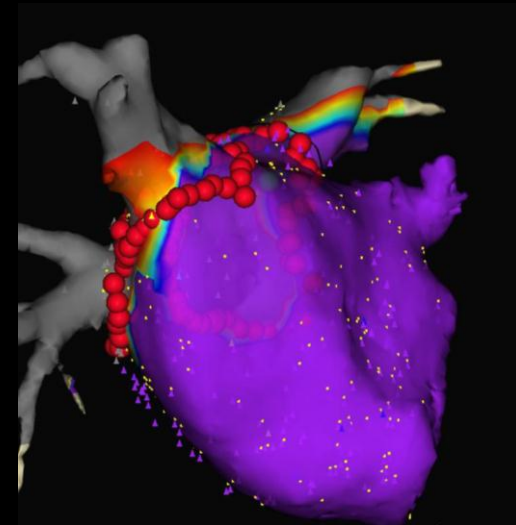
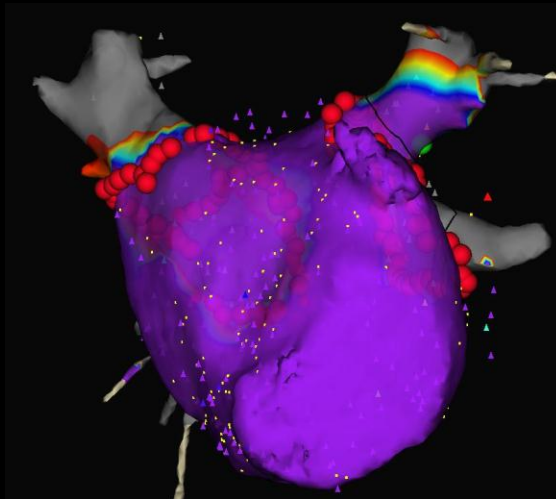
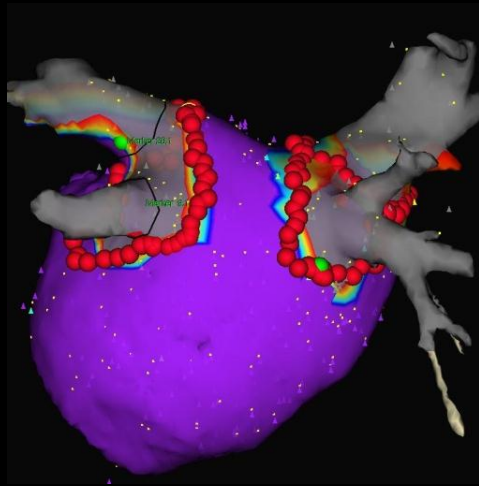
Stellenwert bildgebender Verfahren in der invasiven EP

Visualisierung des Erfolgs bei AF Patienten



Individualisiertes Läsionskonzept entsprechend Fibrose

Voltage Map nach zirkumferentieller PV Isolation



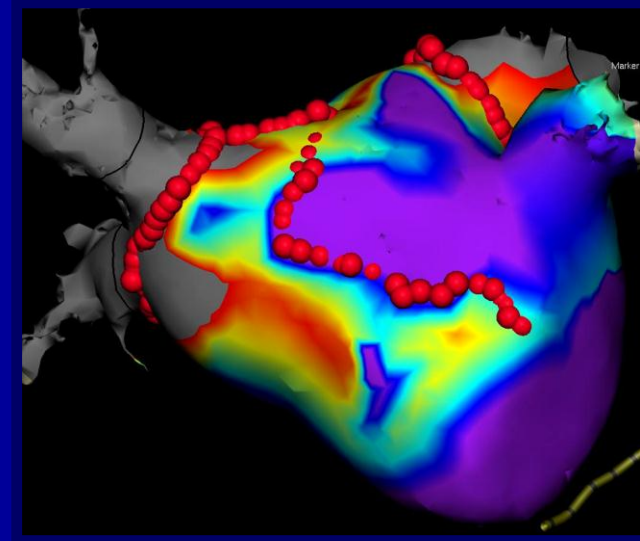
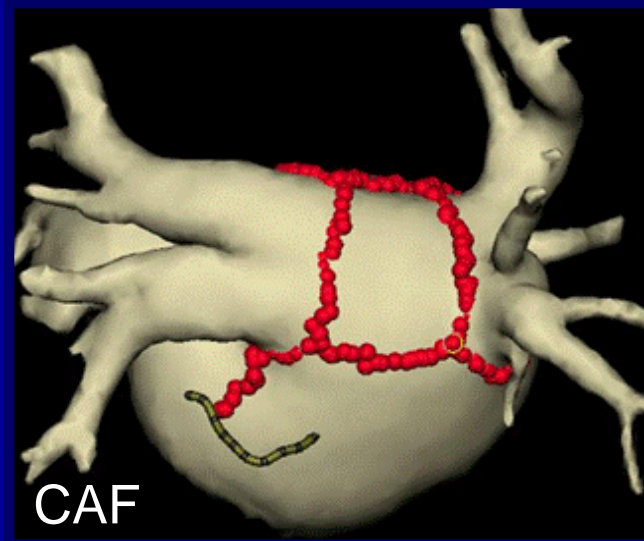
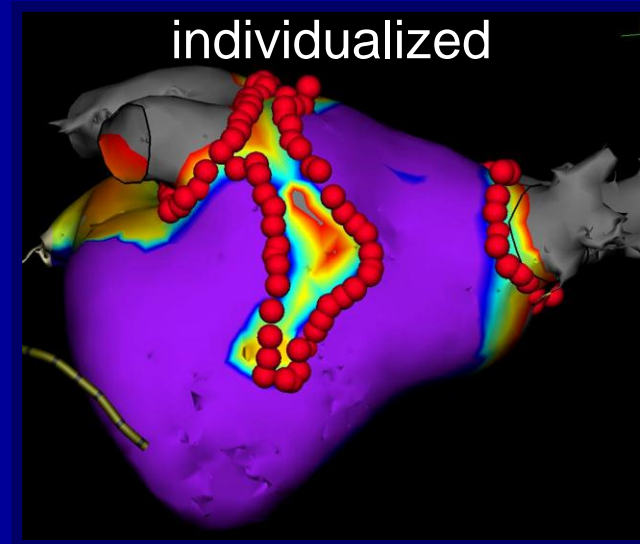
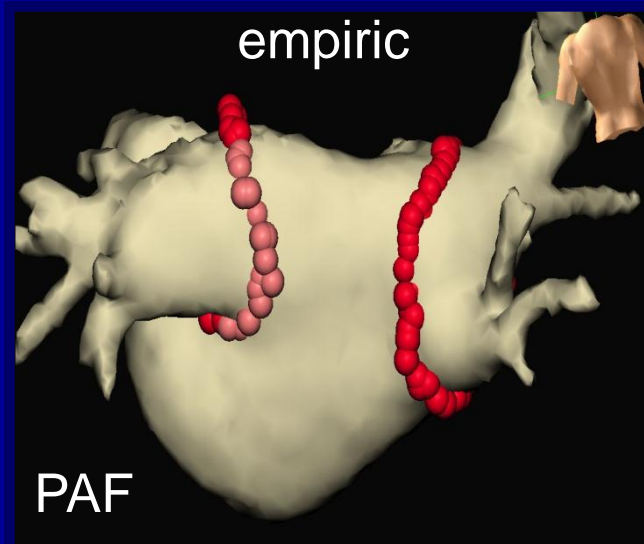
Mapping Punkte: 120

Low Voltage : 0.2 - 0.5 mV

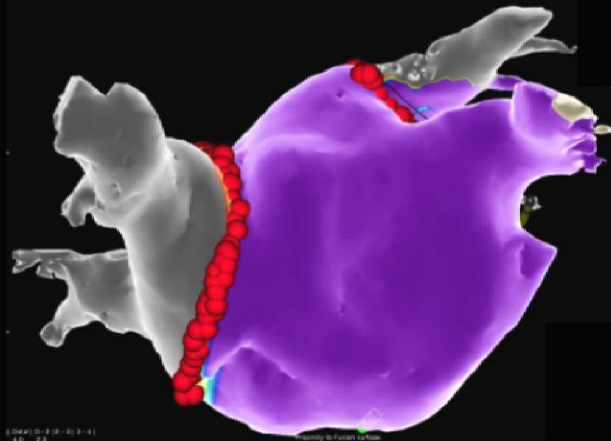
Max. Voltage: 4.3 mV

Follow-up @ 6 Mo: Sinusrhythmus

Individualisierte Behandlung von AF



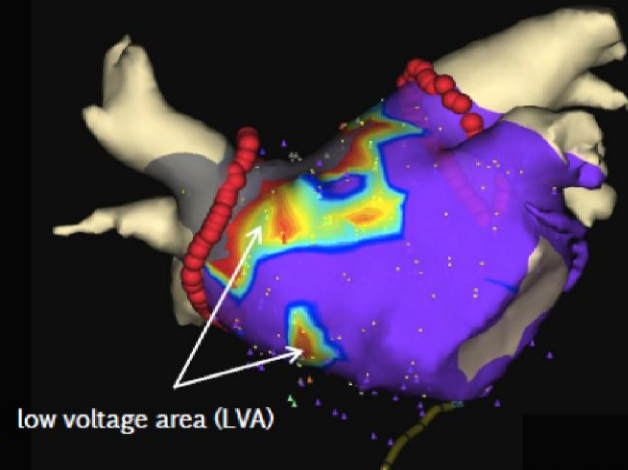
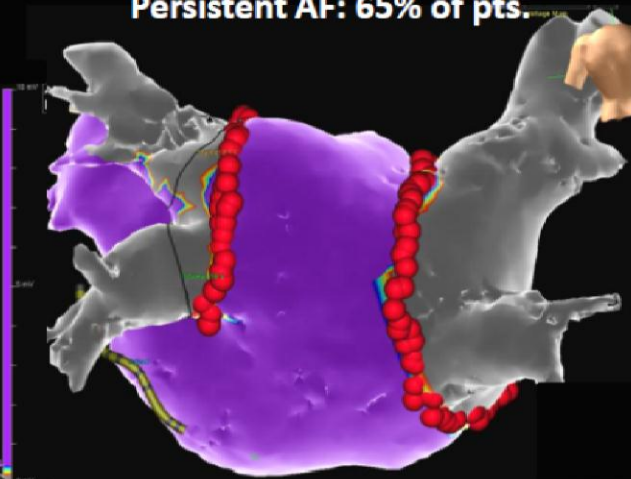
Individualisierte Behandlung von AF



„Healthy“ Left Atrium

Paroxysmal AF: 90% of pts.

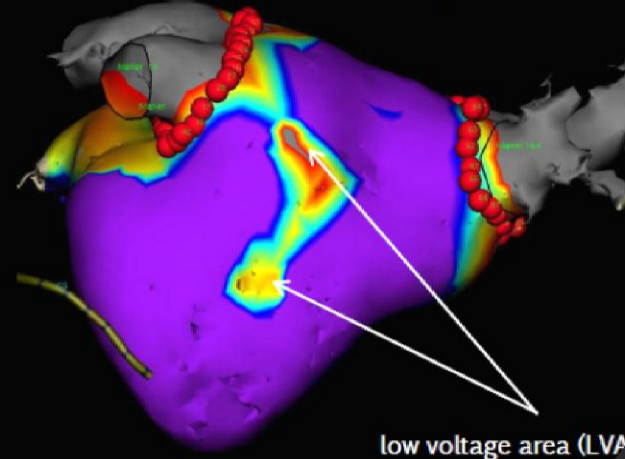
Persistent AF: 65% of pts.



Left Atrium With Substrate

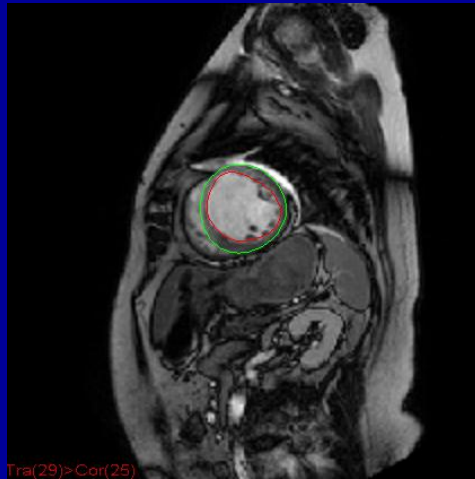
Paroxysmal AF: 10% of pts.

Persistent AF: 35% of pts.

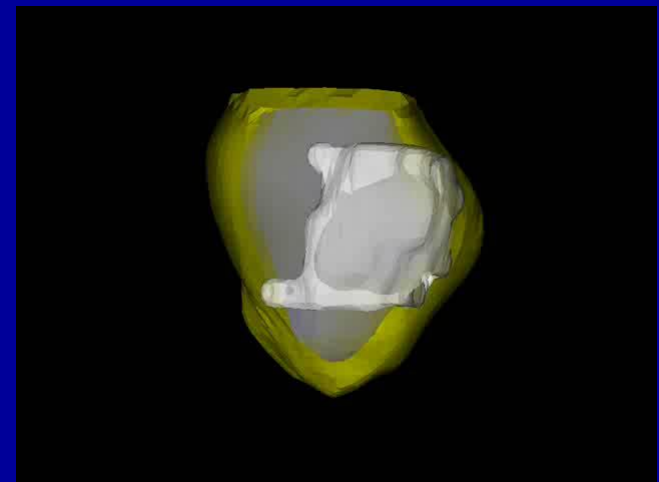
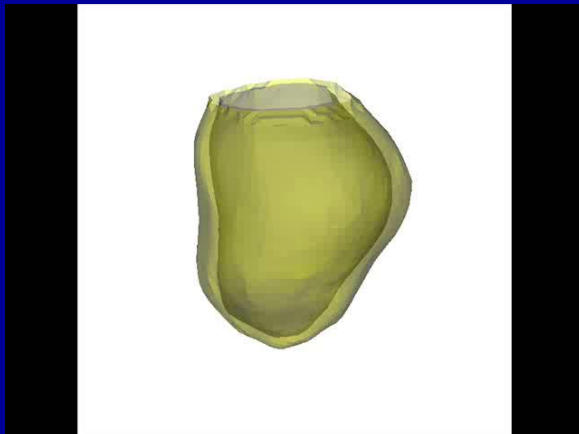
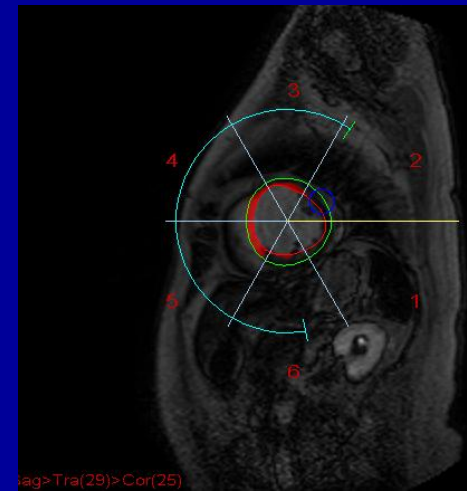


Nachweis von Ventrikelnarben mittels Kardio MRT

Cine MRI enables 3D+t reconstruction of epicardial and endocardial walls

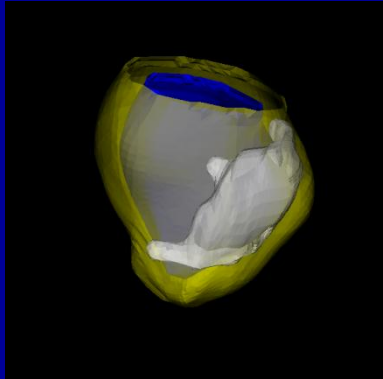


DE-MRI allows precise identification and delineation of scar tissue



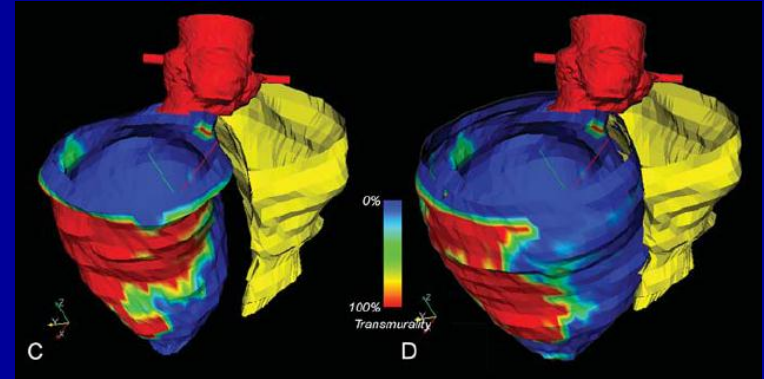
Anatomische Informationen

Multi-surface rendering

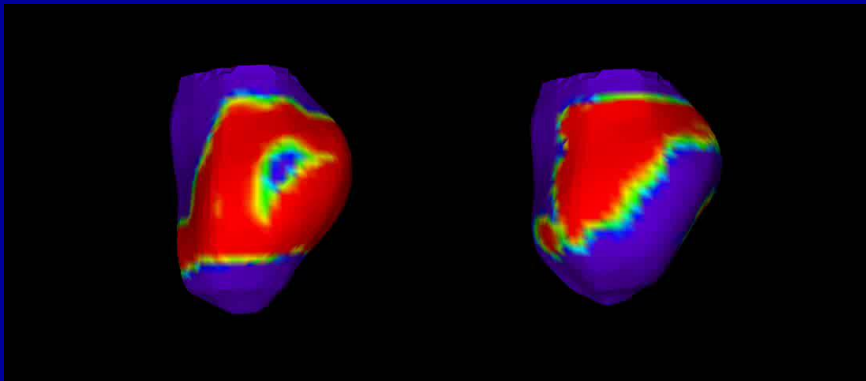


- Other anatomical regions?
- Static vs. Dynamic?

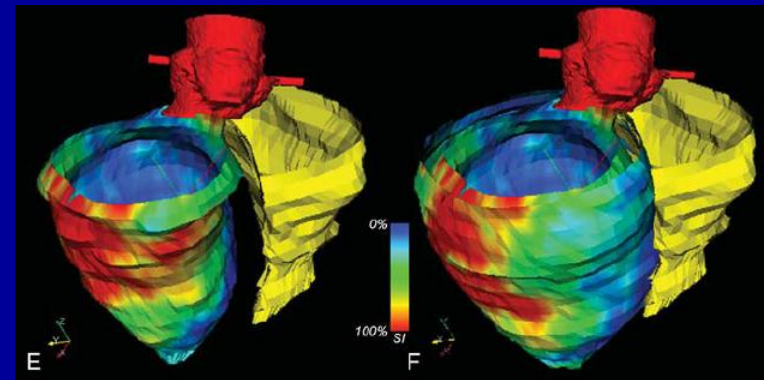
Transmurality



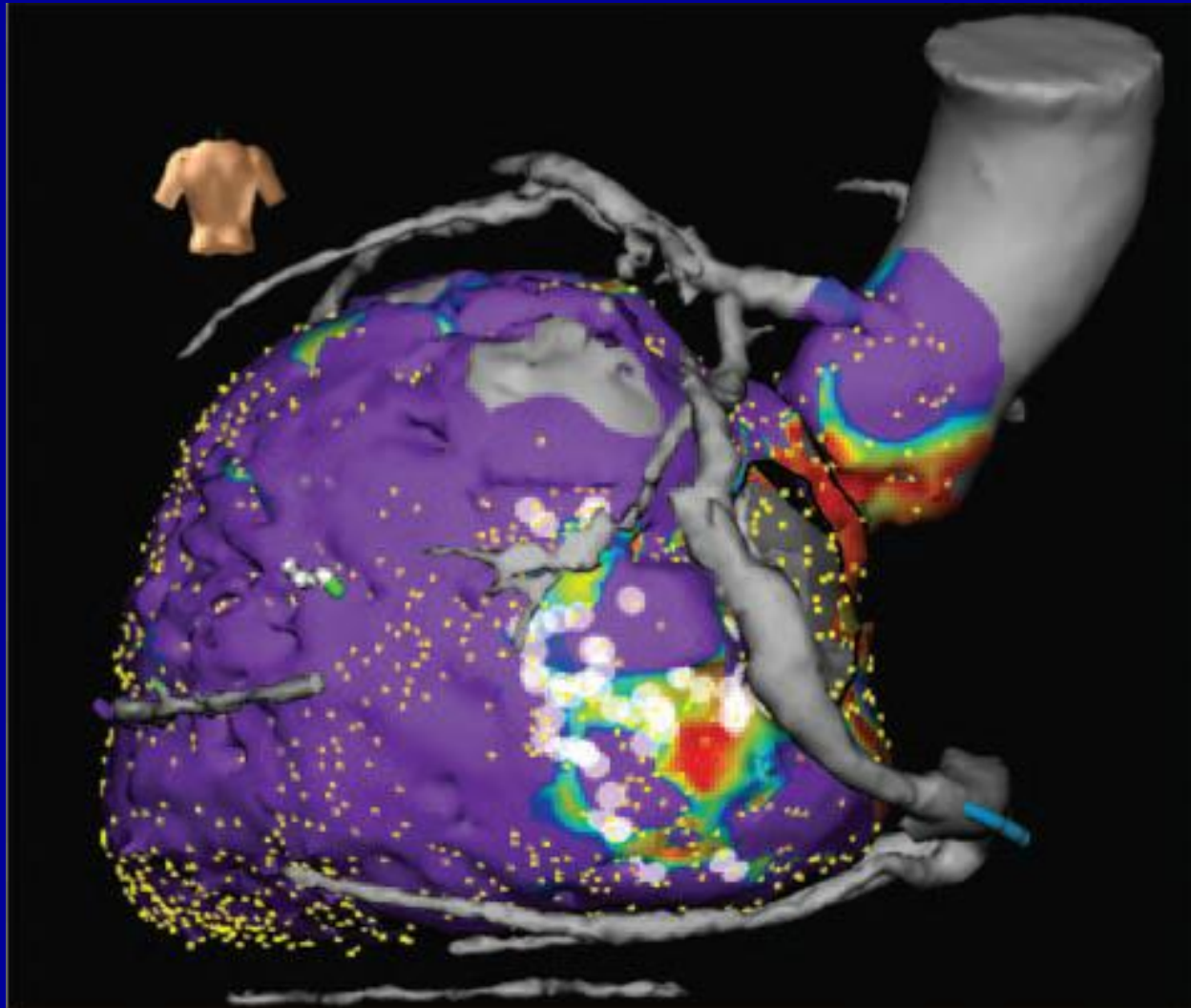
Distance from 3D scar



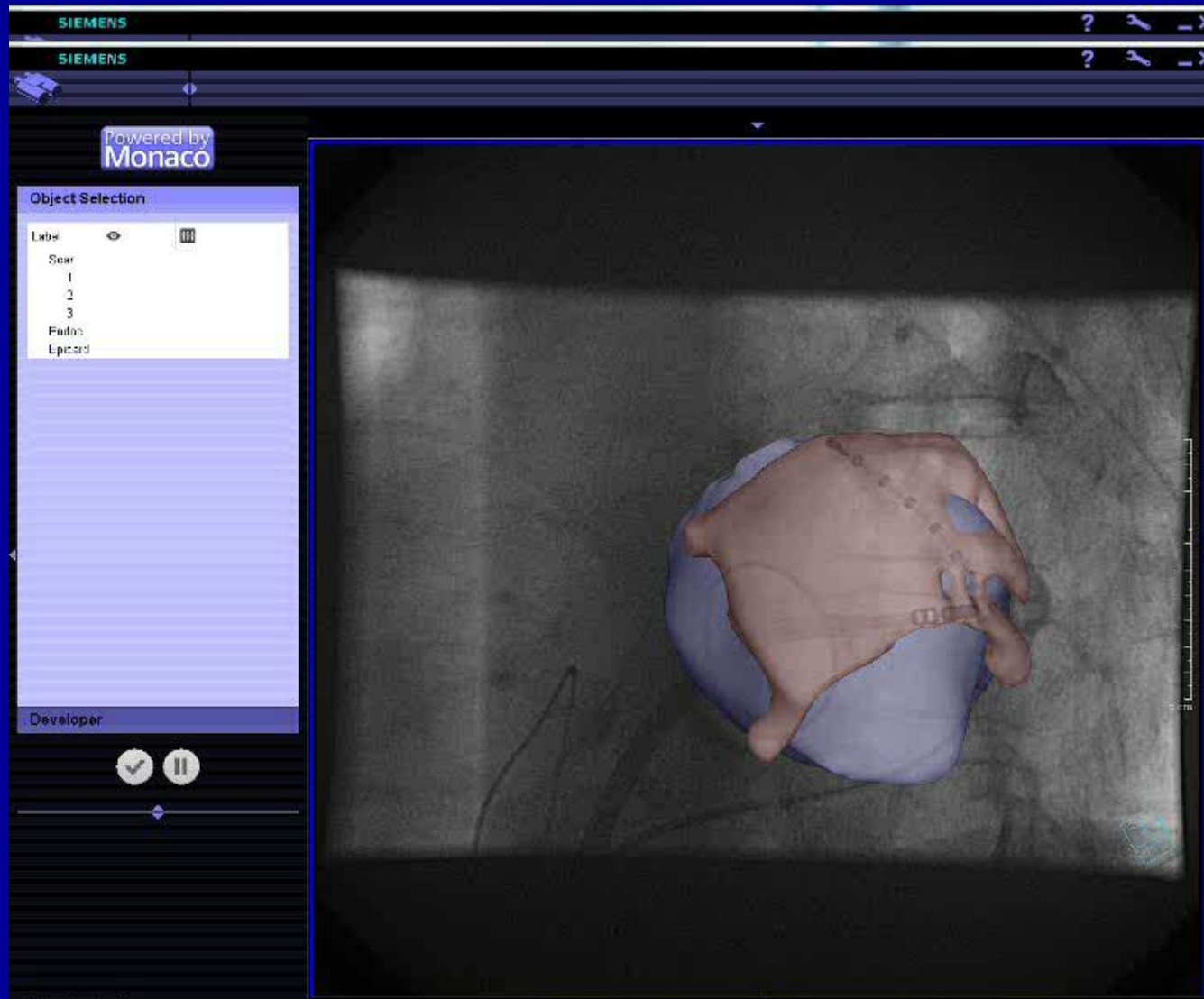Signal intensity – border zone



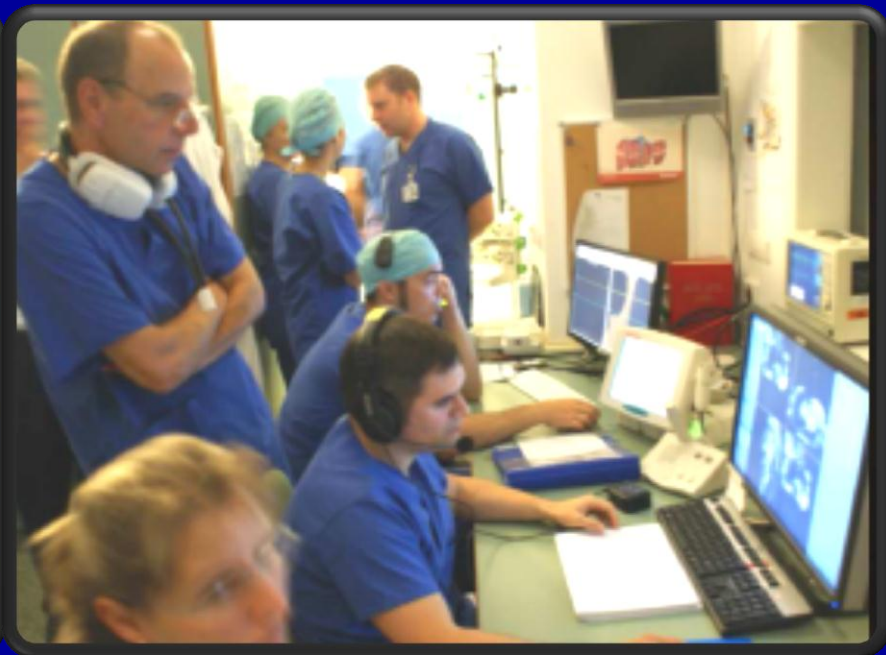
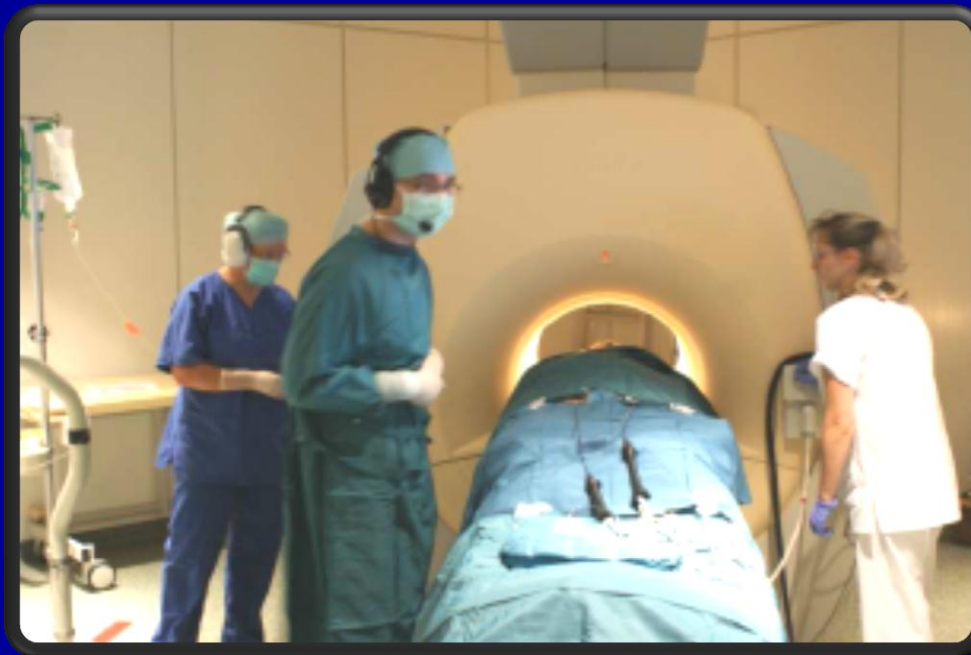Epikardiale Ablation



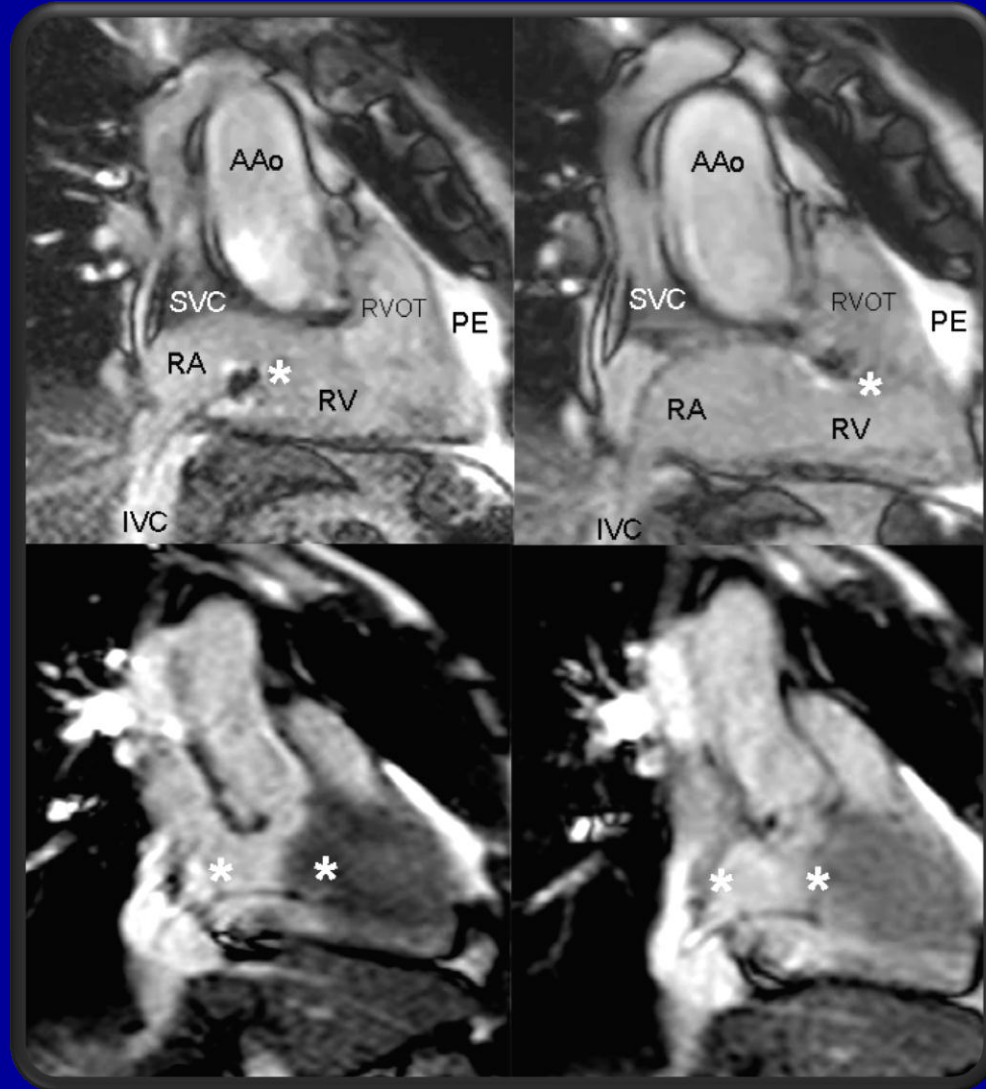
Vision einer Image-geführten VT Ablation



ImriCor: EPU/ Ablation im MRT



ImriCor: EPU/ Ablation im MRT

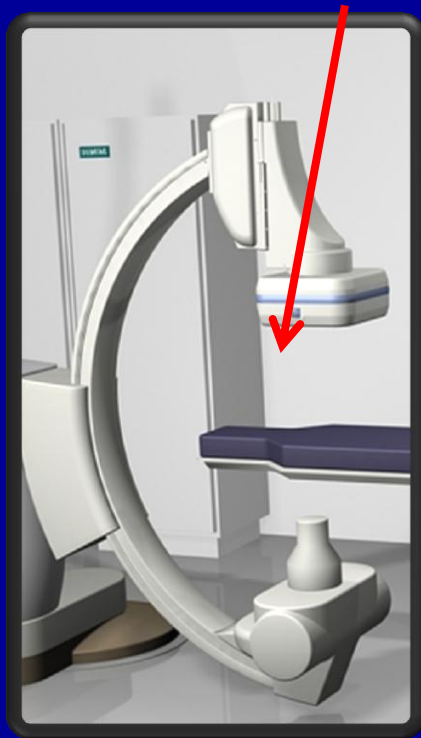

Agenda:



- 1.) Einleitung
- 2.) Rolle der CT
- 3.) Rolle der MRT in Planung und Durchführung von Ablationen
- 4.) Reduktion der Fluoroskopiezeiten

Future of intracardiac catheter navigation (Mediguide)

3D electromagnetic field
integrated into the
fluoroscopy detector



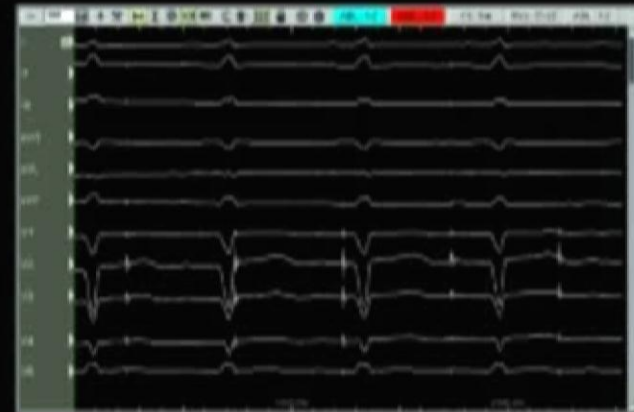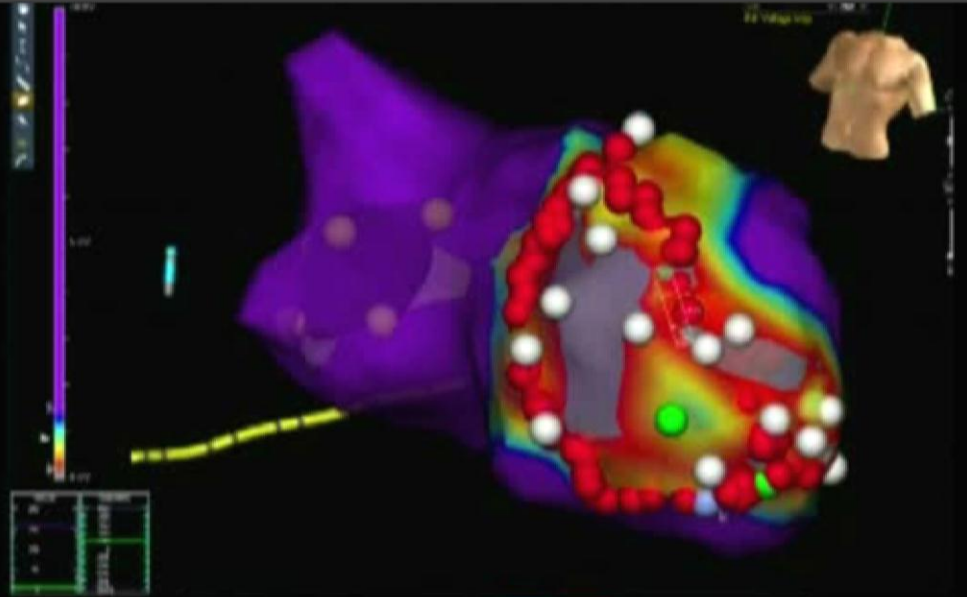
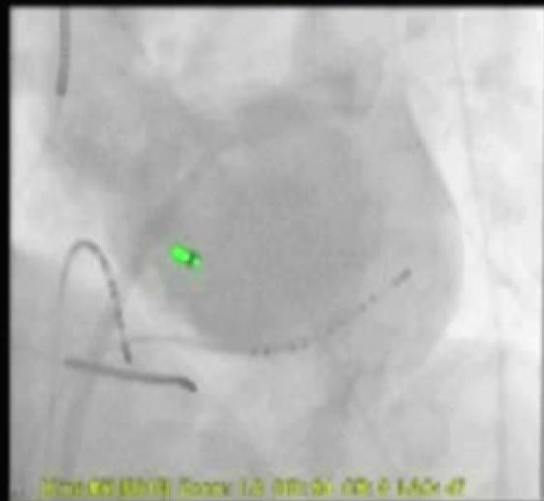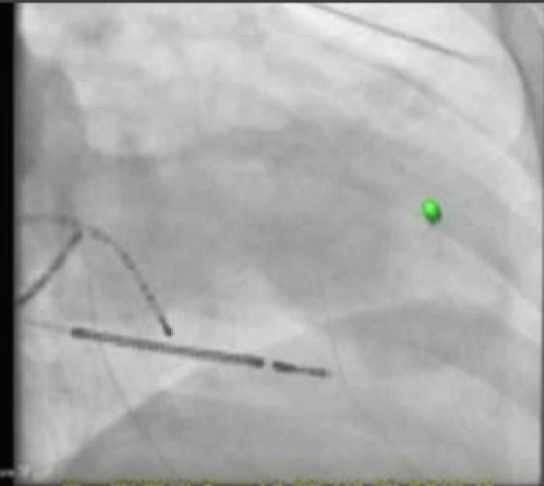
miniaturized sensor
technology



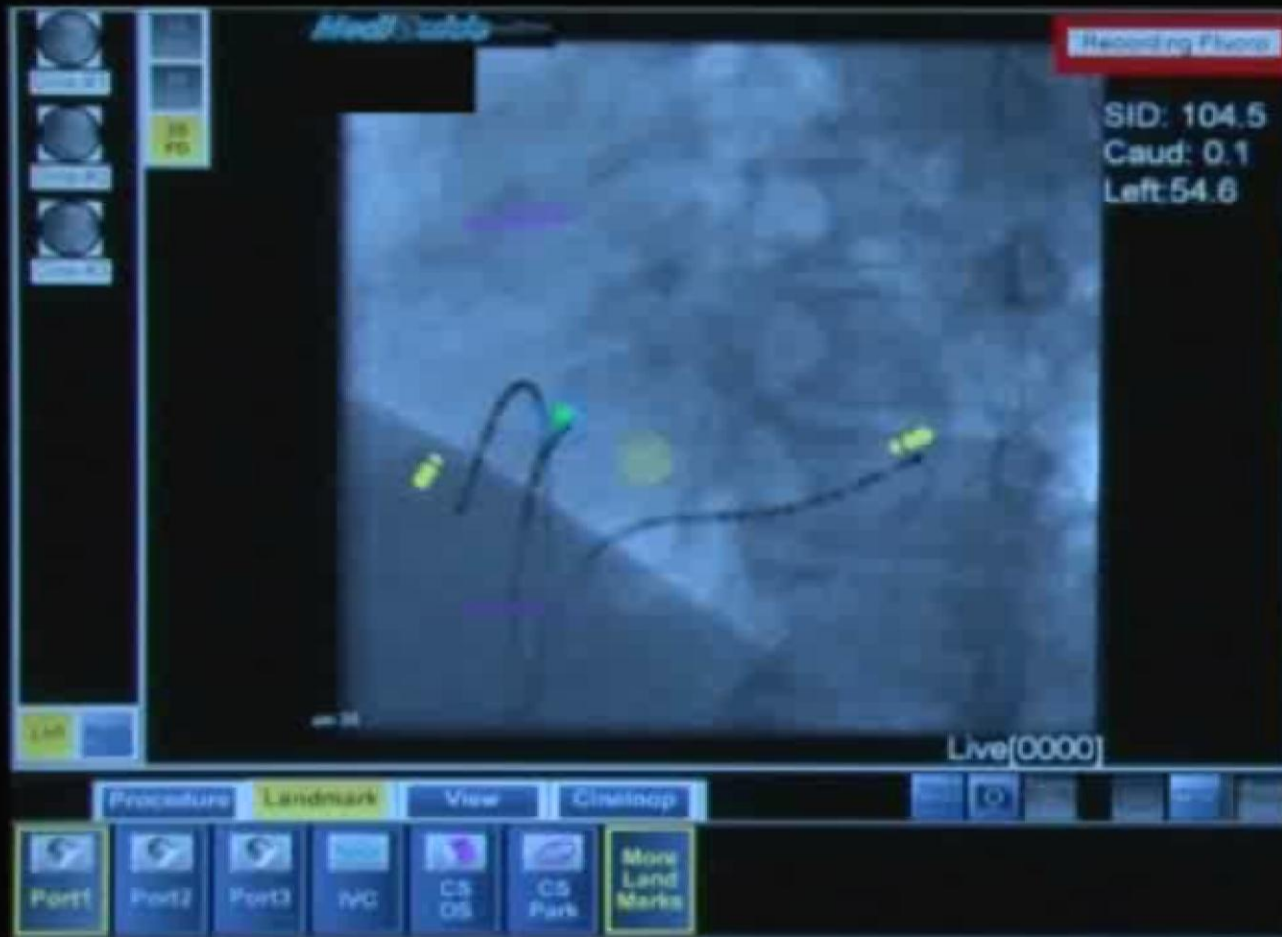integration with
3D cardiac mapping
system (NavX)



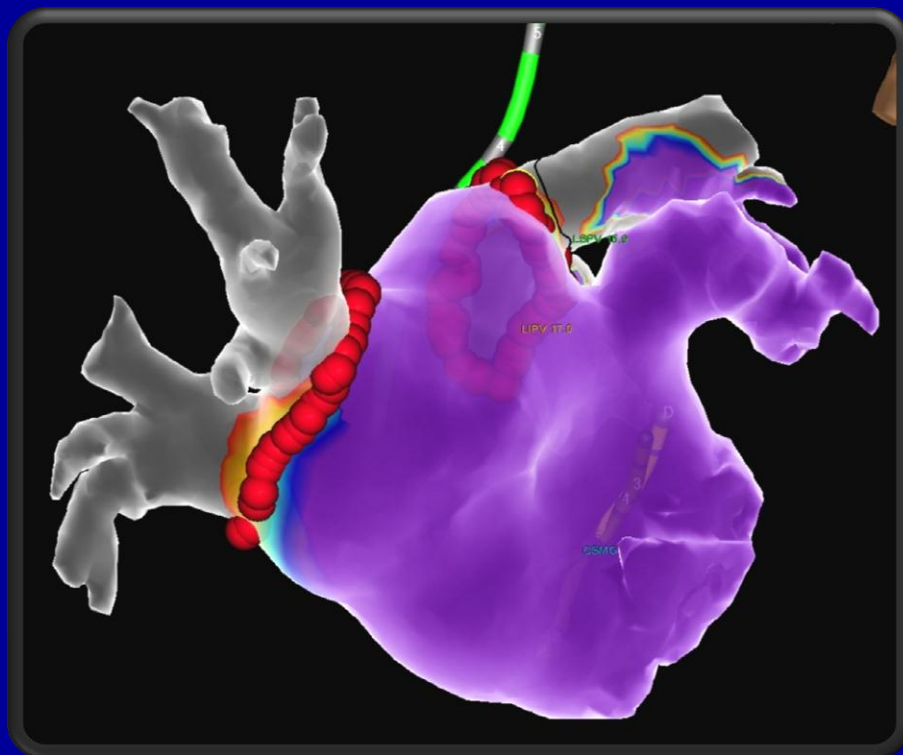
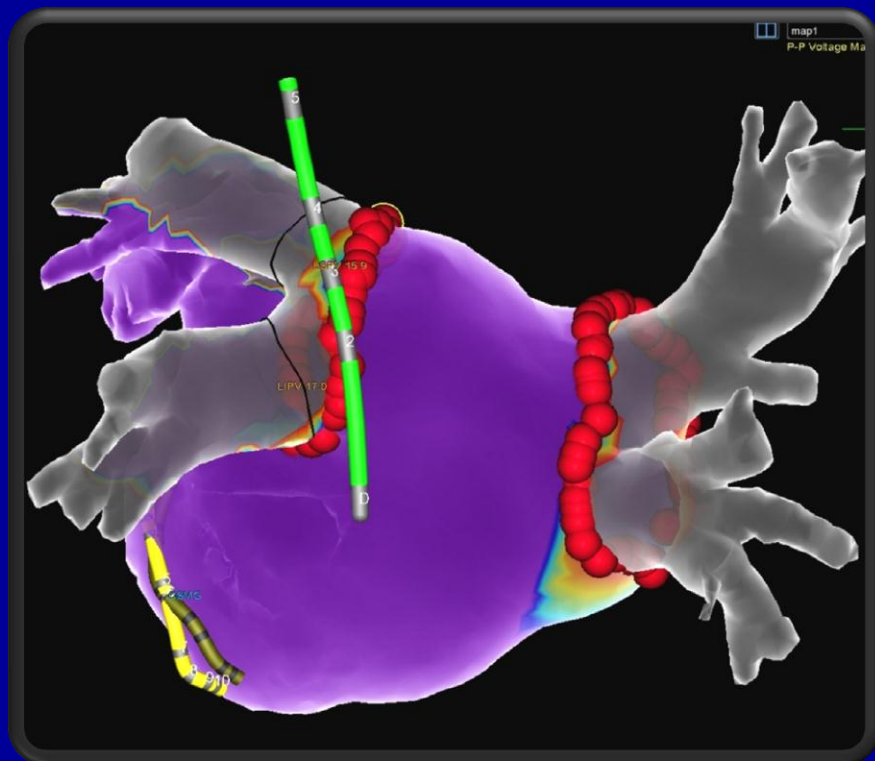
Stellenwert bildgebender Verfahren in der invasiven EP



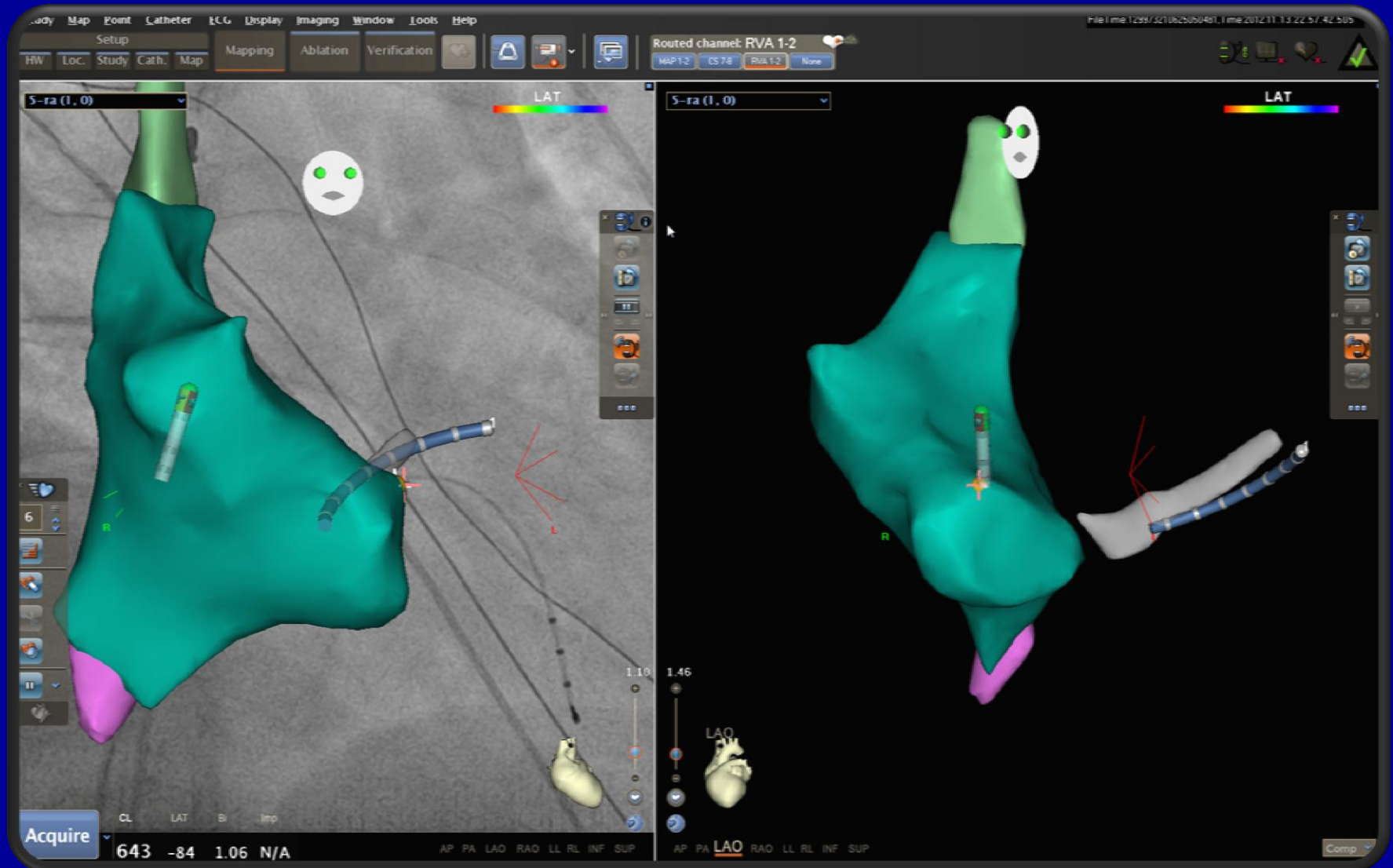
MediGuide (gMPS): AF Ablation



PVI mit MediGuide®: 40s Fluoroskopie



Fluo-Overlay mit Carto 3®: Alara



Zusammenfassung

- Kardiale Bildgebung ist in der EP von großer Relevanz in
 - 1.) Vorbereitung und Planung eines Eingriffs
(Substratanalyse bei VT, potentiell auch bei AF)
 - 2.) Durchführung eines Eingriffs (Bildintegration)
- Kombination anatomische/funktionelle Informationen wünschenswert, derzeit „under progress“.
- In naher Zukunft können evtl. substratbezogene Ablationen im MRT direkt durchgeführt werden.

Vielen Dank!